

I/A and Pupilloplasty

Hytham El Shawaf, MD, FRCS







Brief case presentation

- Male patient
- 29 years old
- Vague history of previous ocular surgery
- Transverse corneal nebula
- Large superior iridectomy
- Complicated cataract






We go to surgery...

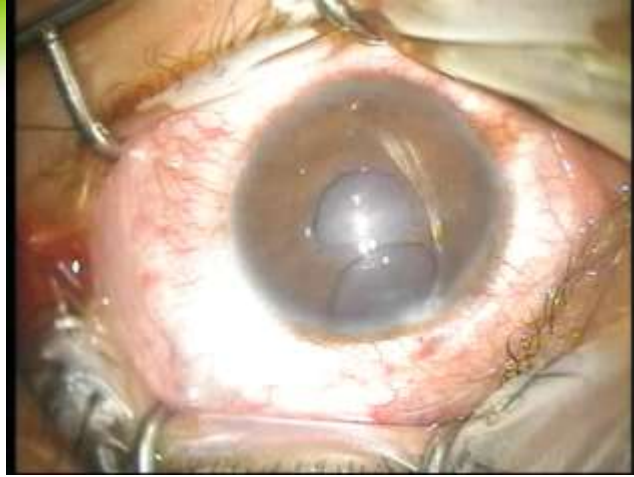Dealing with the narrow pupil

How to manage that pupil?

- Pharmacological
- Mechanical
 - Stretching
 - Hooks and rings
 - Sphincterotomies



Thinking outside of the box





