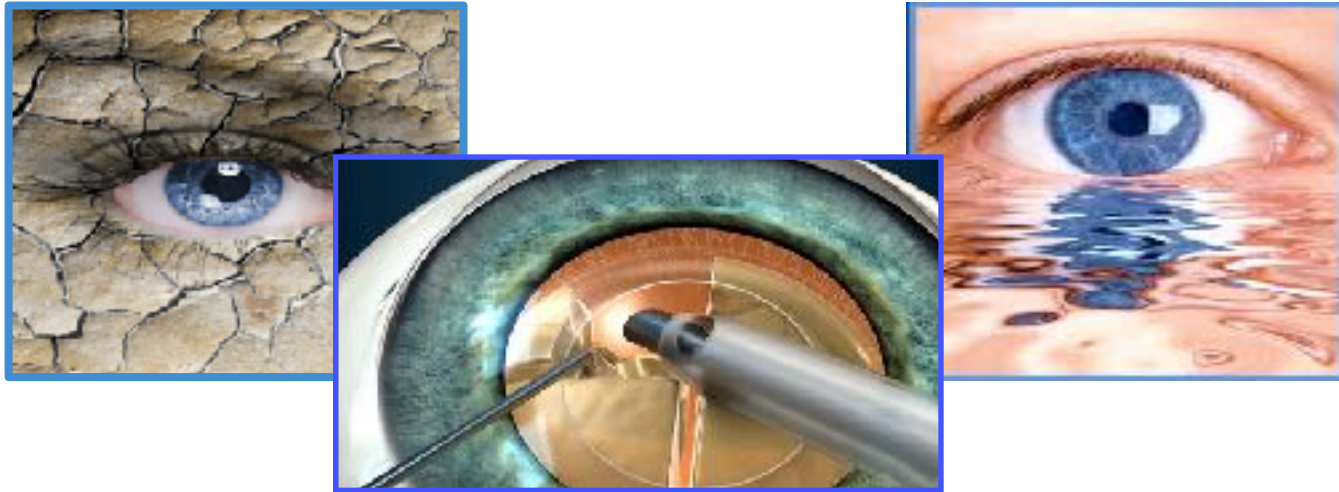

Phaco-refractive Surgery & Dry Eye

Tamer M. El-Raggal, MD, FRCSEd

Professor of Ophthalmology,
Ain Shams University

No Financial Interest

Tear Film

Lipid Layer

0.1 μm

Meibomian glands

Prevent evaporation of tears

Aqueous layer

7.0 - 8.0 μm

Lacrimal gland

Provides nutrition and oxygen to cornea

Hydrates and provides smooth optical surface

Bacteriostatic

Mucin layer

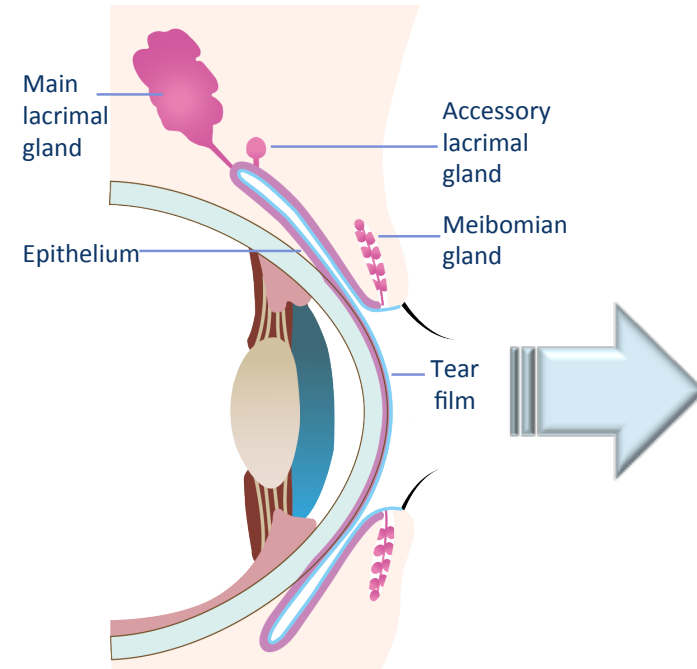
0.02 - 0.05 μm

Conjunctival goblet cells

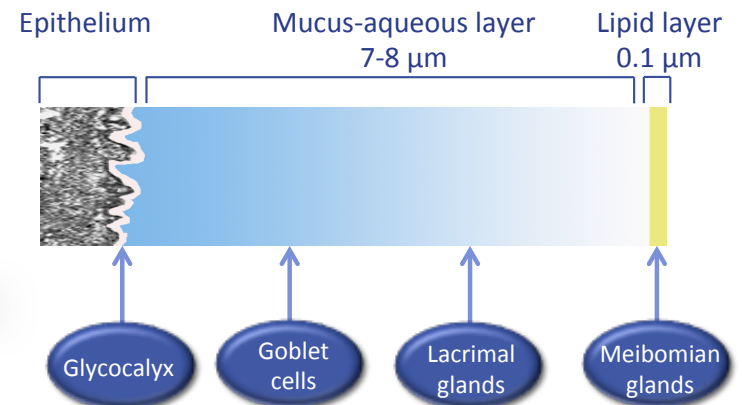
In gradient throughout aqueous layer

Decreases corneal surface tension, making it wettable

Fills surface irregularities



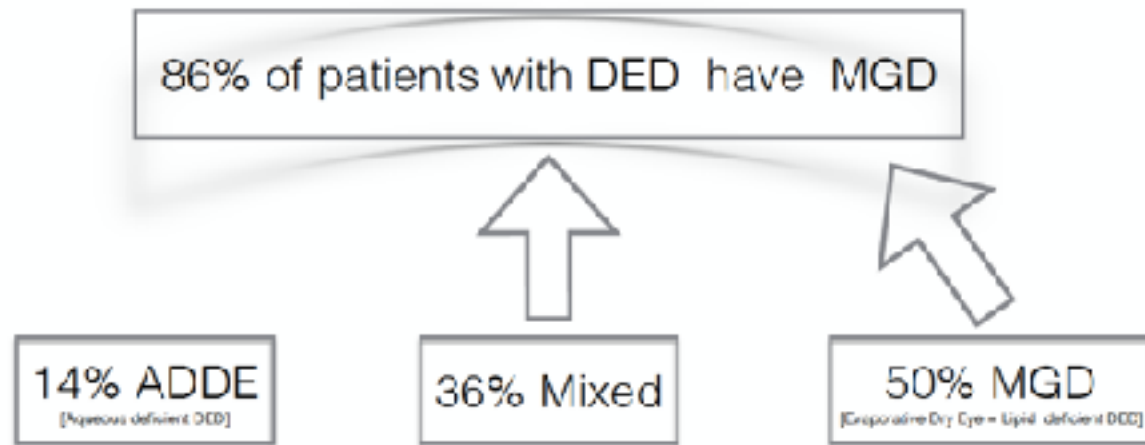
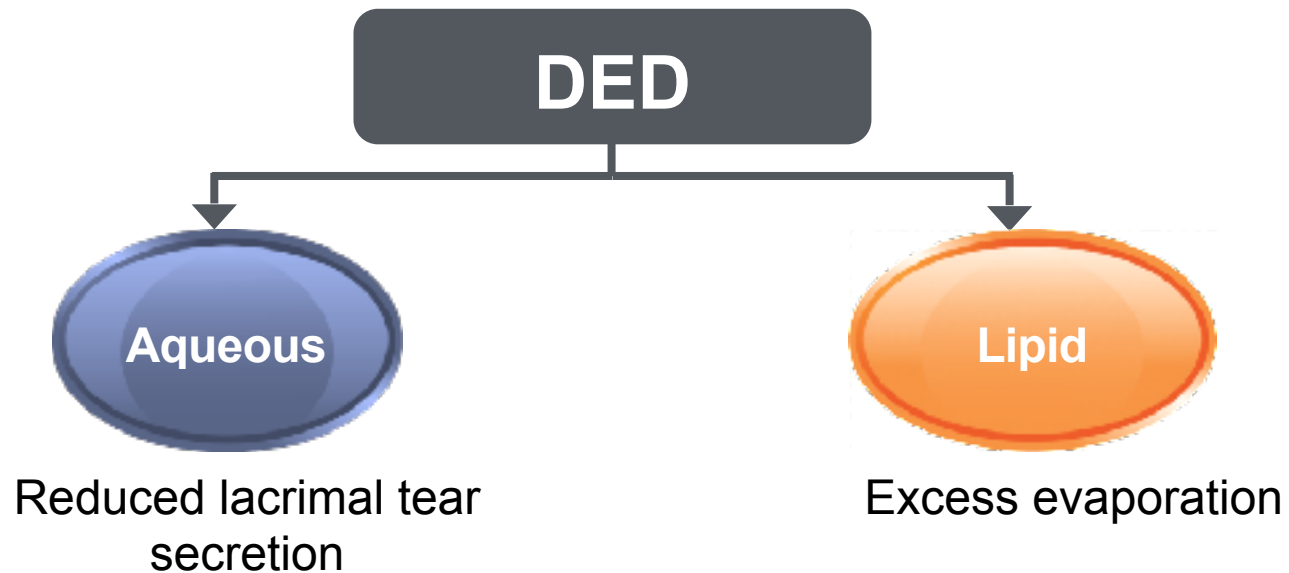
Pre-ocular tear film



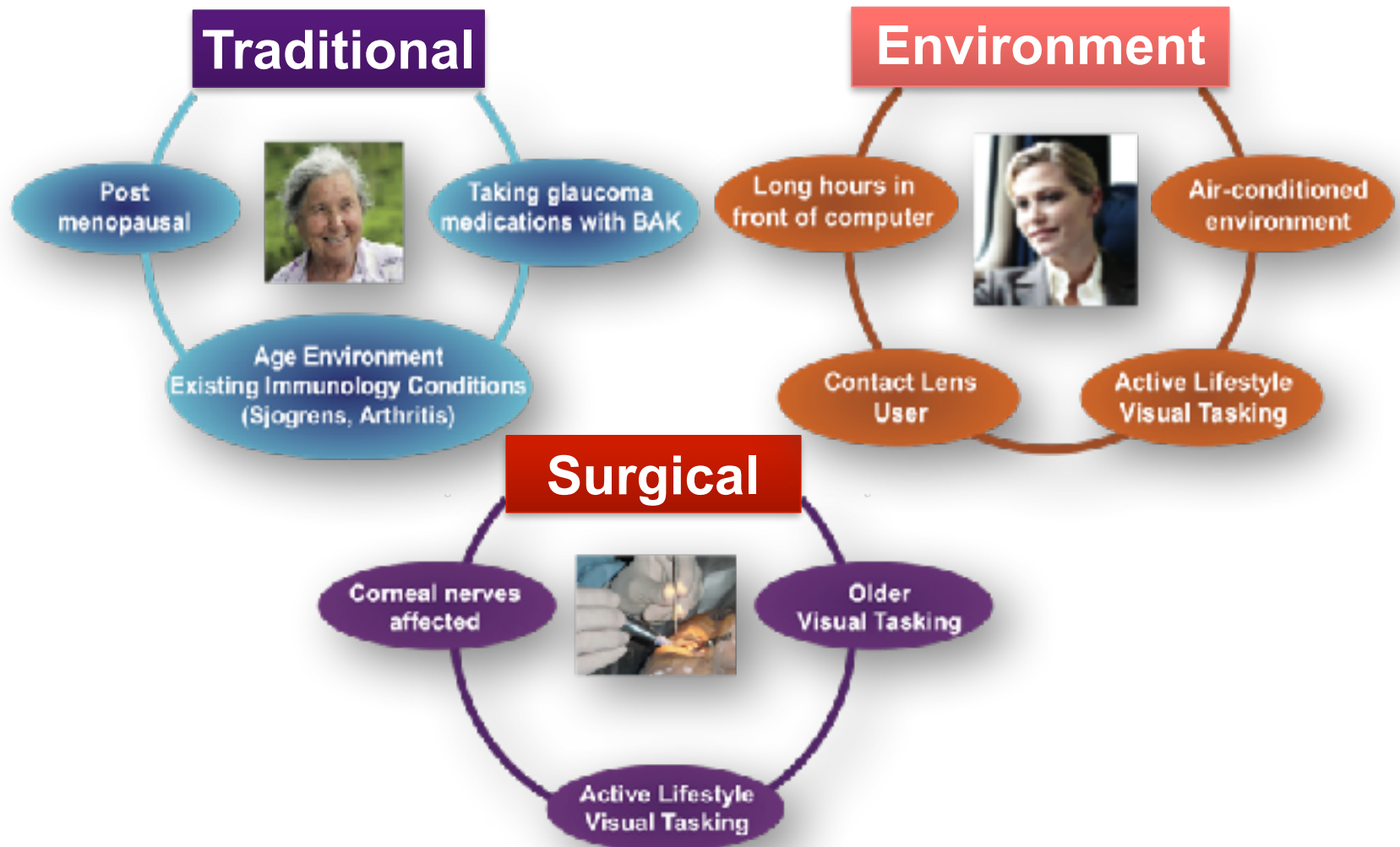Definition and prevalence of DED

“Multifactorial disease of tears & ocular surface that leads to symptoms of **discomfort, visual disturbance** with damage to ocular surface.

- Accompanied by ↑ **osmolarity of tears** & ocular surface **inflammation**”.
- 5-30% > 50 yrs.
- Females more commonly affected.



Causes of Dry eye

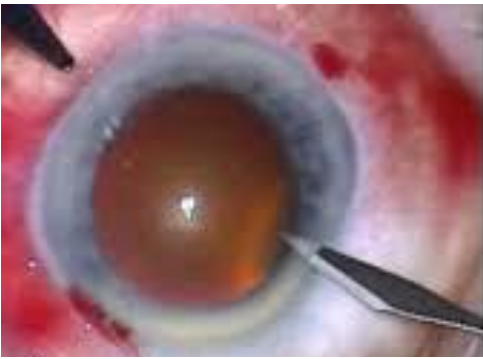

PHACO SURGERY

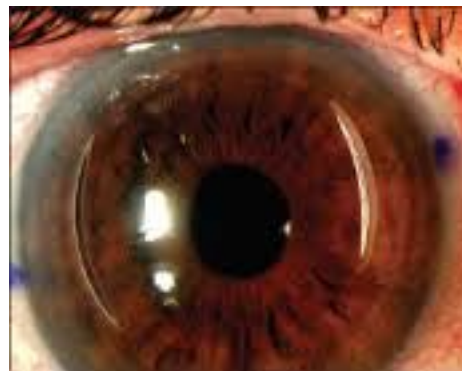


- Up to 30 % of patients undergoing cataract surgery have underlying dry eye (> 50 yrs)
- Elderly patients are more sensitive to medications given before & during cataract surgery, particularly NSAIDs.

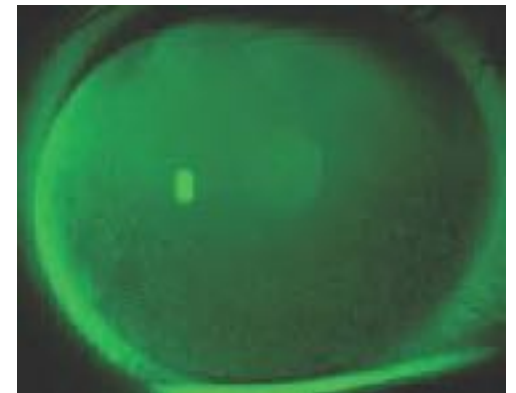





- During clear corneal cataract, large portion of corneal nerves are cut.
- 1ry incision 3.0 mm, paracentesis about 1.0 mm — — total arc length of 4.0 mm of full-thickness incisions.
- Additional incisions for astigmatic correction, as LRIs, cutting of more nerves.



- Surgery induces ocular inflammation, — — — adversely affect tear-film production & stability.
- Postoperative medications — — — ocular irritation & tear-film disruption.
- Fluoroquinolones — — — "medicamentosa", where drug or its solvent cause tear film disruption, PEE & ocular surface inflammation.



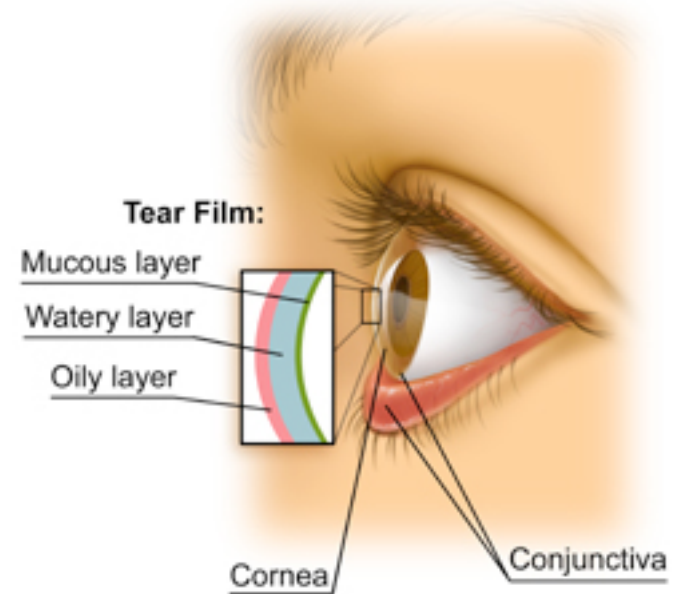
Phaco adds 1 level



| | Severity I | Severity II | Severity III | Severity IV |
|-------------------|---|--|--|---|
| Symptoms | Mild to moderate | Visual symptoms | | |
| Conjunctiva | Mild to moderate signs | Conjunctival stains | | Conjunctival scarring |
| Cornea | | <ul style="list-style-type: none"> • Tear film signs. • Mild peripheral corneal staining | <ul style="list-style-type: none"> • Marked corneal P.staining. • Central corneal staining. • Filamentary keratitis | <ul style="list-style-type: none"> • Severe corneal staining. • Corneal erosions. |
| TBUT | varies | ≤ 10 | ≤ 5 | Immediate |
| Schirmer | varies | ≤ 10 | ≤ 5 | ≤ 2 |
| Treatment options | Environment. M. - Watery intake. Stop relevant drugs. - Preserved tears. - MGD. | - Add - Unpreserved tears. - Cyclosporin A. - Topical steroids. - Punctal plugs. Omega 3. | - Add - Tetracyclines. - Moist chambers - CL - Autologous serum | • Add • Systemic anti-inflammatory. • Oral cyclosporin. • Acetylcysteine.. • Acetylcysteine. • Punctal cautery • Tarsorrhaphy. |

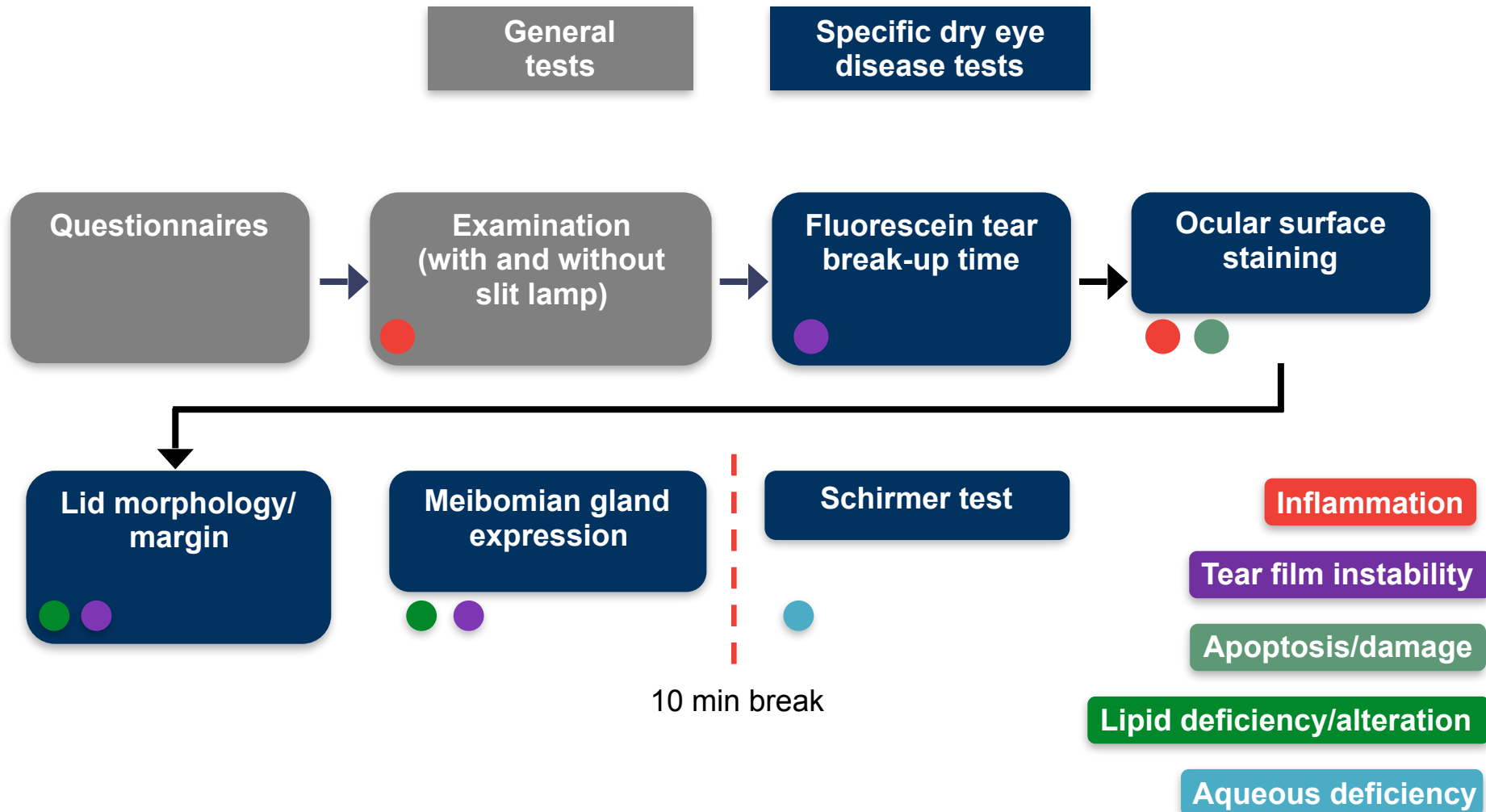
LASIK adds 2 levels





DIAGNOSING Dry eye

A practical test sequence based on DEWS



Tear Film Dysfunction Symptoms

- **Irritation symptoms:**

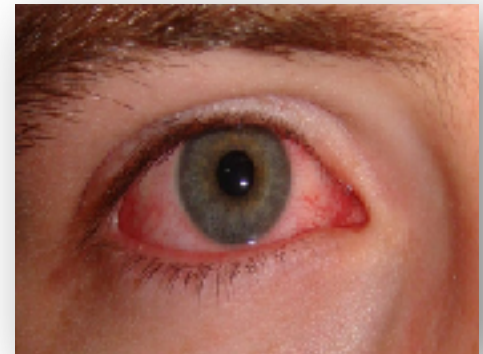
1. Burning, stinging
2. Gritty sensation
3. Sandy sensation
4. Soreness
5. Dryness
6. Sensitivity to air drafts
7. Itching more by end of day

- **Tearing/ discharge symptoms:**

1. Mucus
2. Tearing, more in morning

- **Vision Symptoms**

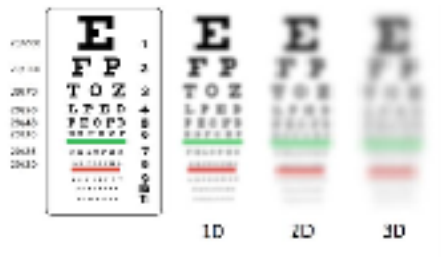
1. Fluctuation
2. Blurring improves with tears
3. Light sensitivity



Dry Eye Affects Quality of Life




- Percent of patients reporting interference with daily life:
 - Night time driving 32.3%
 - Reading 27.5%
 - Computer work 25.7%
 - Watching TV 17.9%



DED interaction with phaco-refractive surgeries

- Distortions induced by disruption at ocular surface is magnified by some premium IOLs [MF, Aspheric].
- This can severely degrade both visual acuity and visual quality in most demanding cases.




"I was better before doctor!!!"

Diagnosing Tear Film Abnormalities

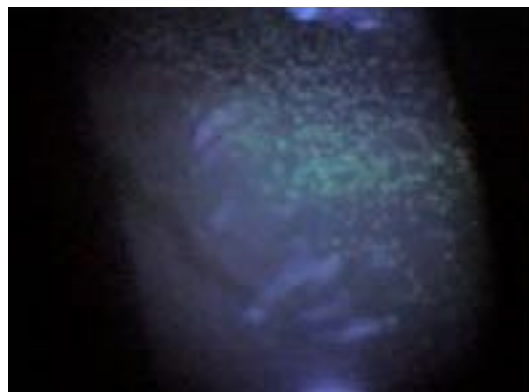


Tear Film Break Up Time

Lipid →



OCULAR SURFACE

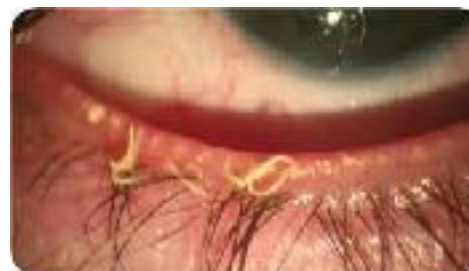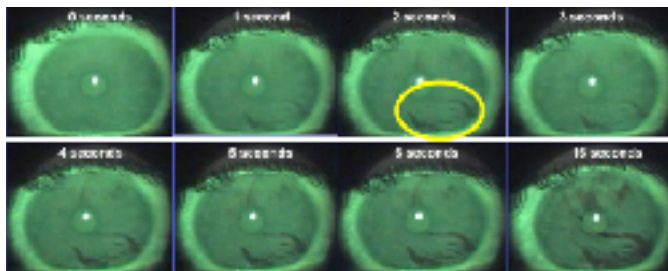

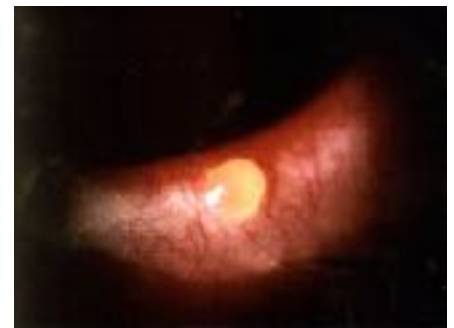
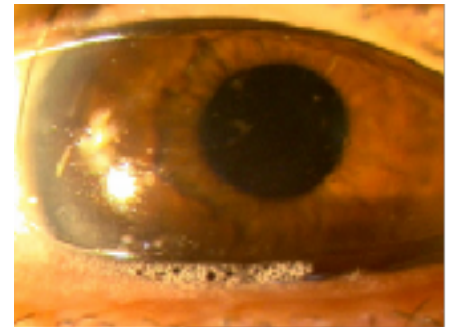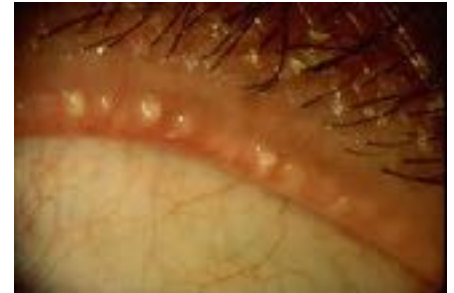Corneal Staining

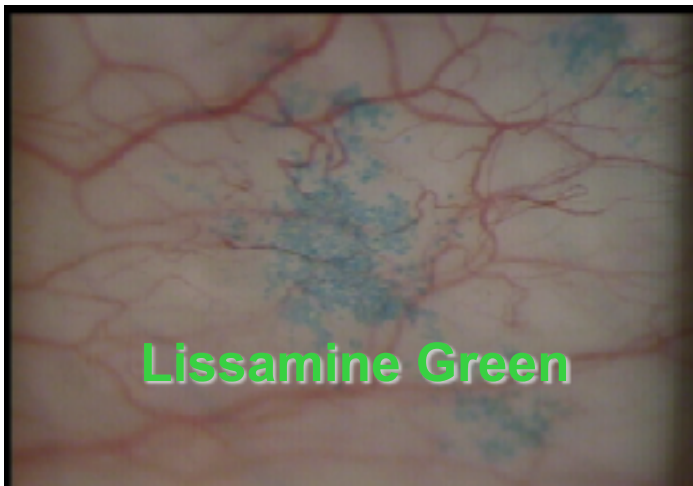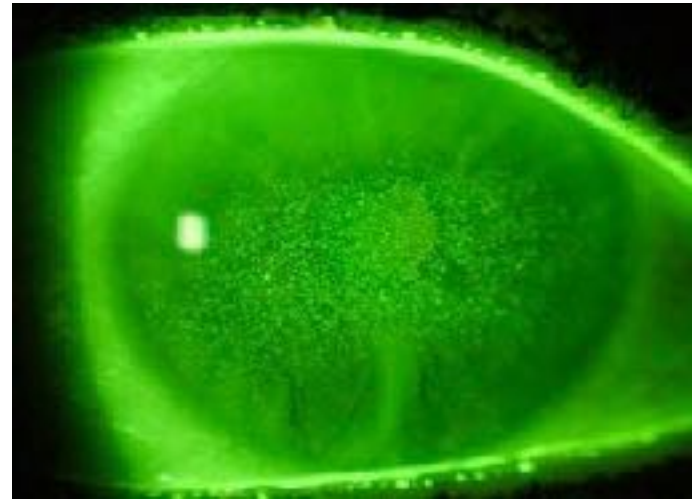
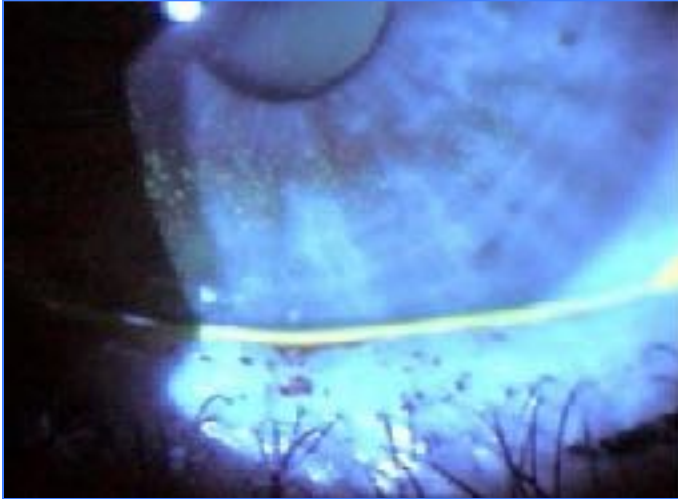
Aqueous/Mucin →

Clinical Signs of Lipid Deficiency

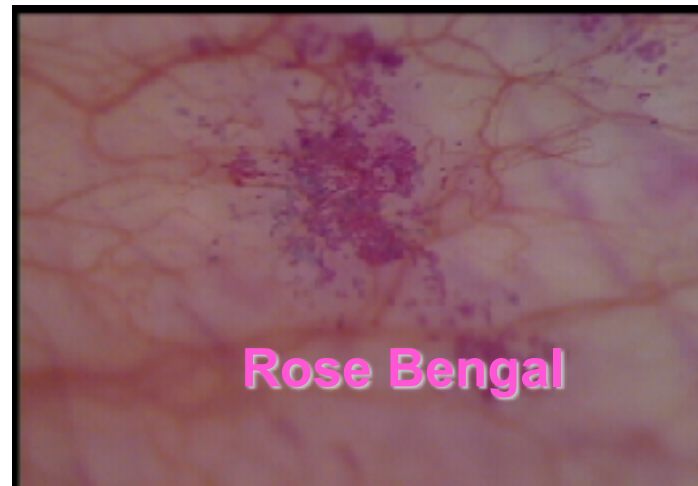- Poor lipid production and/or composition:
 - Obstruction of meibomian glands
 - Change in gland secretion
- Repeated styes, chalazion
- Tear film instability and rapid BUT



Aqueous/Mucin Deficiency - Corneal and Conjunctival Staining

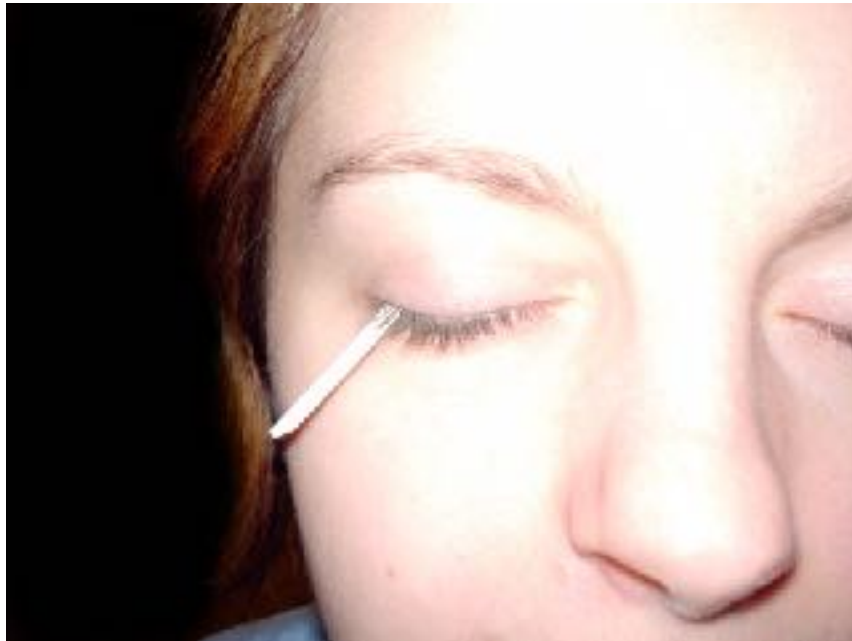

Lissamine Green

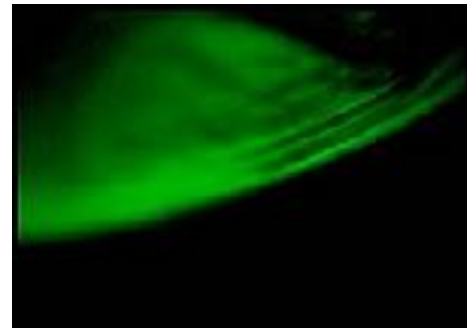

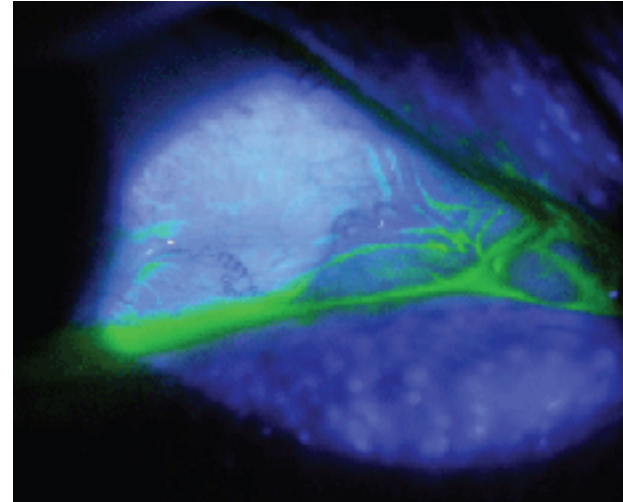


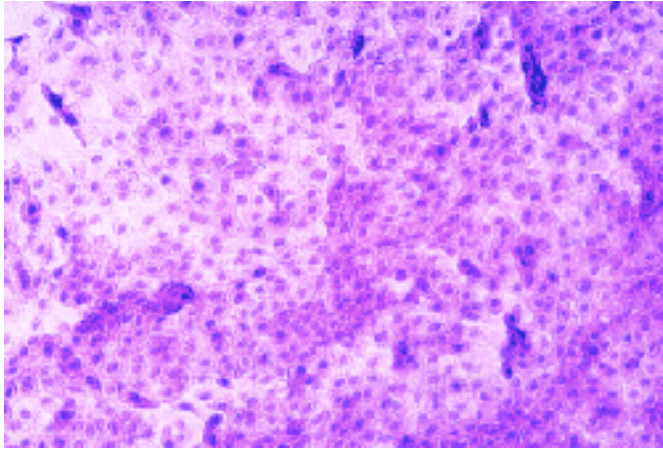
Rose Bengal

Schirmer test

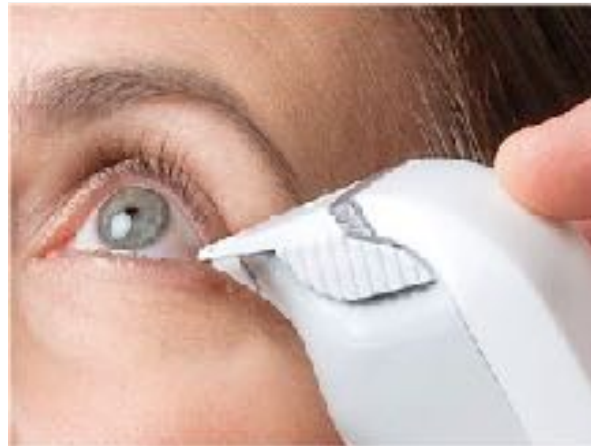

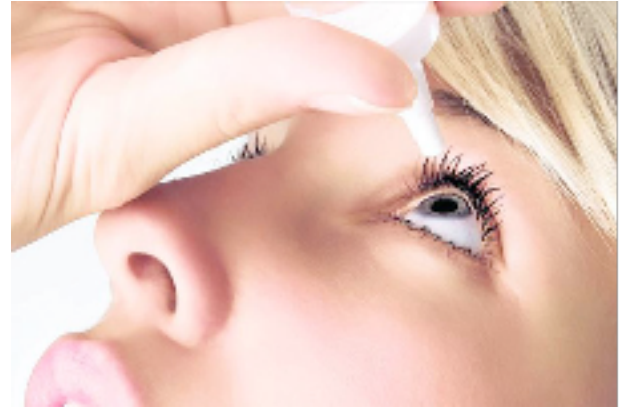Marginal tear meniscus & LIPCOF





Other Tests

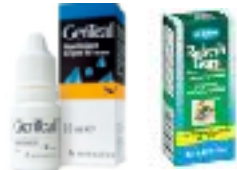



Dry Eye Treatment

Types of Lubricant Eye Drops

Cellulose Derivative Products



Glycerin Containing Products



Hyaluronic Acid Containing Products



Polyethylene & Propylene Glycol Products



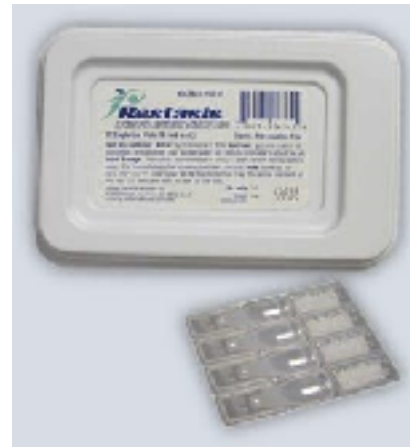
Oil-Containing Emulsion Products



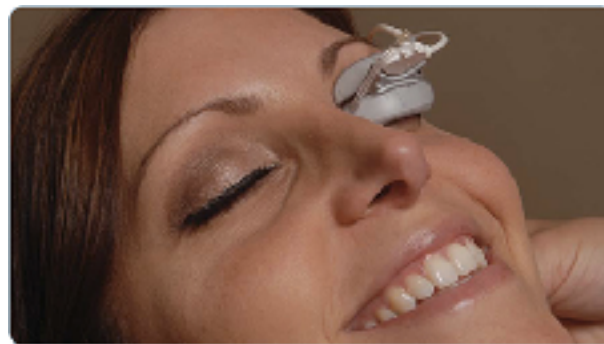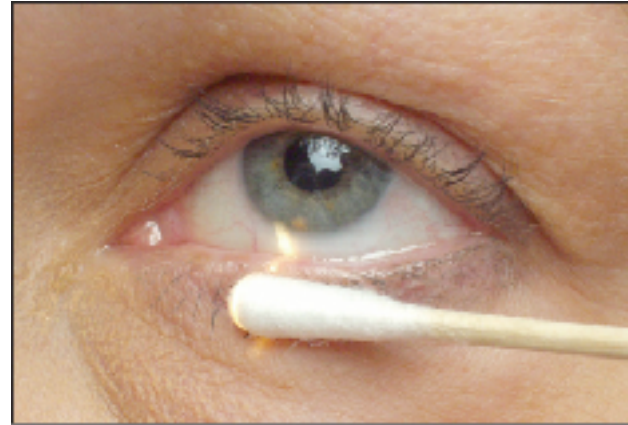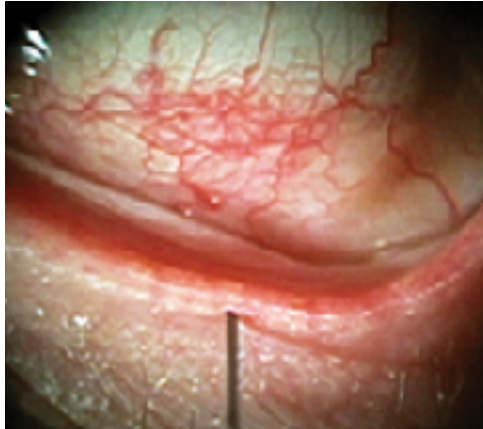
Other LINES Of Treatment



- Cyclosporins
- Serum
- Steroids
- Tetracyclins
- Omega 3

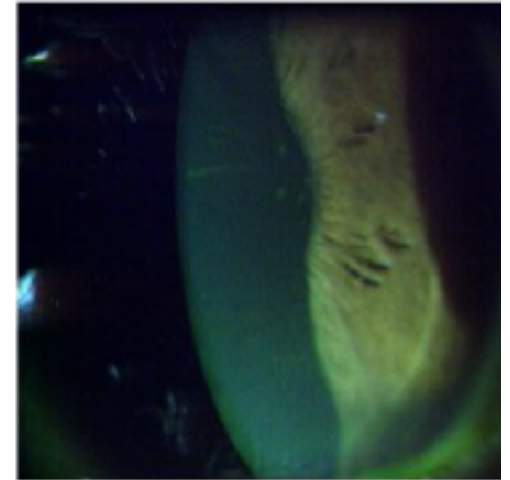
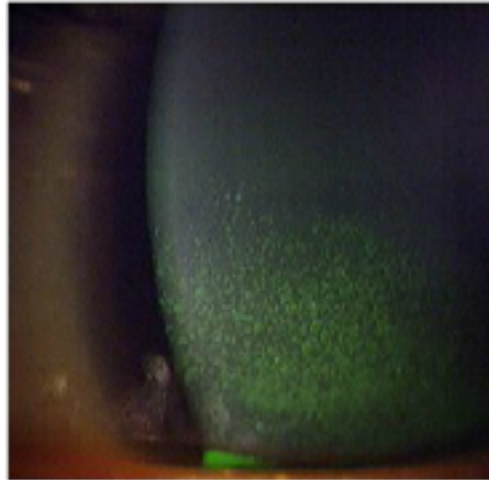
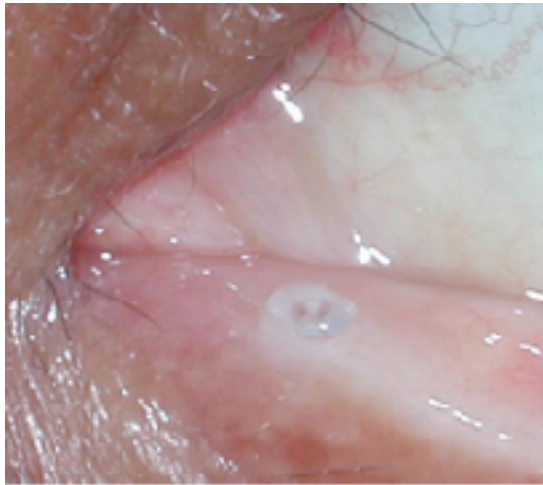
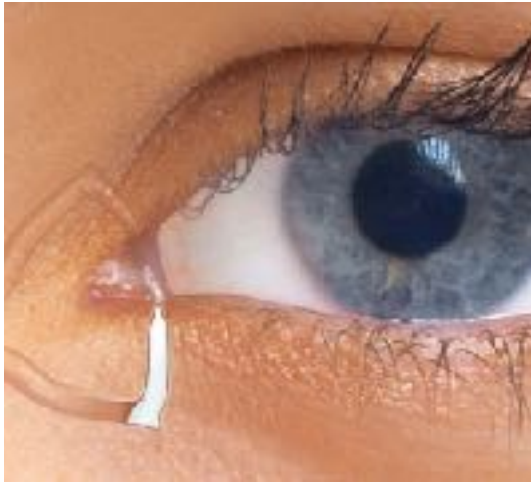
Meibomian gland probing & expression





Punctal plugs



Conclusion

- DED is common & often under-recognized.
- Multifactorial in origin & categorized to aqueous or lipid deficiency.
- Dry eye is a major problem in phaco & refractive patients.
- Tell patient before better than after surgery.

Conclusion

- Preoperative assessment & ocular surface preparation is mandatory.
- The level of severity of DED definitely influence operative details.
- Maintaining healthy ocular surface is essential for achieving best visual outcome.
- Many tear substitutes available. Also consider other ttt lines.

Thank you

Email: telragal@me.com