

Research Institute of Ophthalmology, Cairo
11th International Conference, 3-4 February, 2017

CATARACT SURGERY IN UVEITIS

Professor Harminder Singh Dua

MBBS, DO, DO(Lond), MS, MNAMS, FRCS, FRCOphth., FEBO, FRCP, FCOptom, MD, PhD

Chair and Professor of Ophthalmology

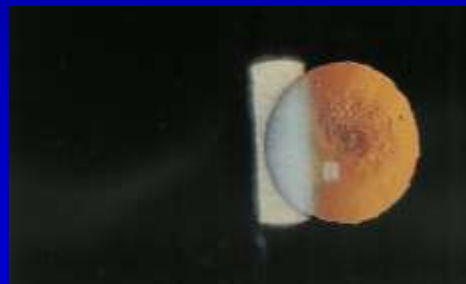
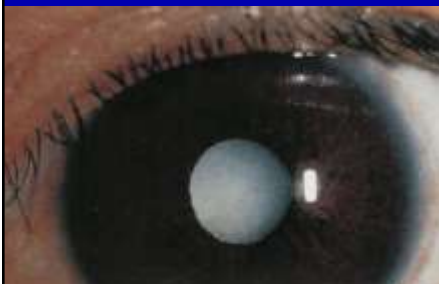

THE STARTING POINT

Type of cataract:

Complicated: Posterior subcapsular, Mature Milky
Steroid induced (PSC)
Senile

Key to success is Planning and Anticipation. The Theory is more important than the Surgery



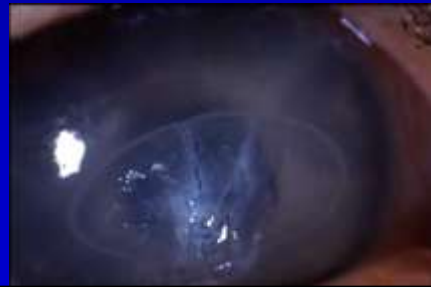PRE-OPERATIVE CONSIDERATIONS

Patient consent: Explanation of risks

- Exacerbation of inflammation
- Pressure problems: Low or High
- Vision problems: transient or permanent
- Need for post-op medications and surgery

Clinical examination:

Cornea: Endothelial count and pachymetry where possible. Band keratopathy. Will influence position of incision and use of viscoelastic and phaco power.

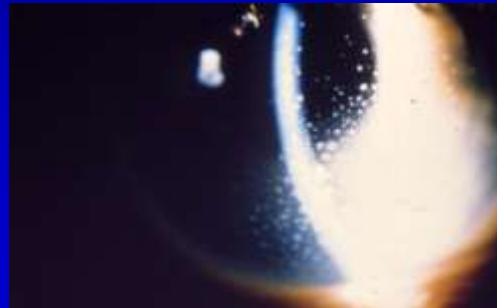
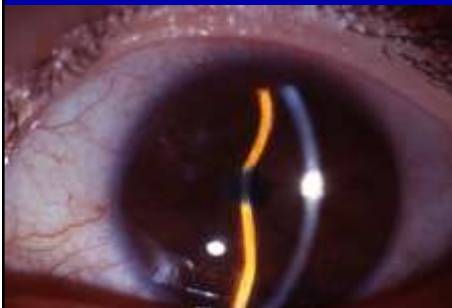
AC: **Shallow** – anticipate iris bombe, Intumescent cataract
Deep – possible luxated lens held by adhesions, hypermature shrunken lens

Flare and Cells – treat vigorously. Some cells may always be present

Seclusio pupillae, Iris Bombe (probe injury)

Granulomatous Keratic precipitates

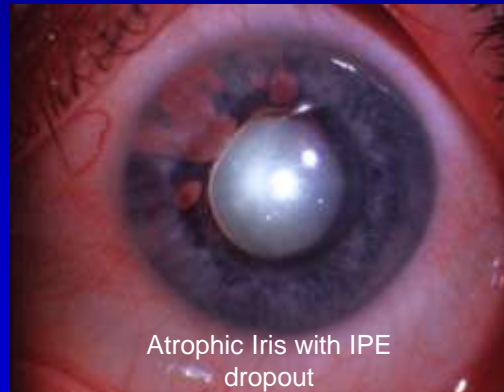



PRE-OPERATIVE CONSIDERATIONS

Clinical examination:

Angle: Gonioscopy – extent of angle closure.
Anticipate post-op pressure problems

Iris: Expect a floppy iris, likely to bleed (new or leaky vessels), adhesions (don't combine with EK)



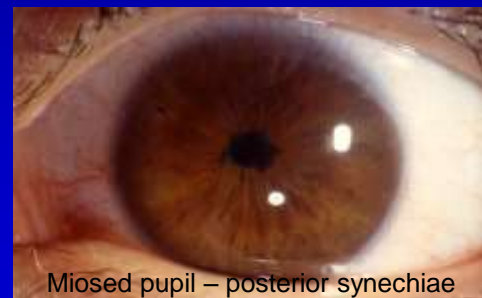
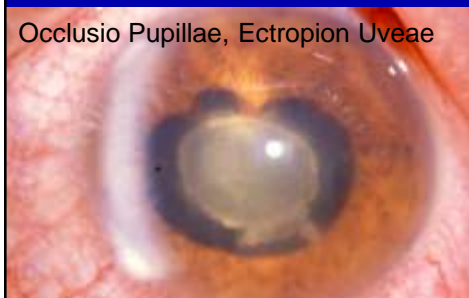PRE-OPERATIVE CONSIDERATIONS

Clinical examination:

Pupil: Synechiae: localised, total (seclusio) or pupillary membrane (occlusio)

Lens: Thin or thick capsule, Weak zonules, possible fluid cortex, possible soft nucleus

Vitreous: Vitreous syneresis or detachment



PRE-OPERATIVE CONSIDERATIONS

Clinical examination:

Visual potential: Causes of poor vision include macular edema, epiretinal membrane, optic nerve pathology (chronic inflammation and glaucoma), vitritis

B Scan ultrasound, Potential acuity meter, Electro diagnostics

Medical treatment:

- Topical or systemic steroids (Oral or Intravenous)
- IOP control
- Mydriatics
- Prostaglandin inhibitors

INTRA-OPERATIVE CONSIDERATIONS

Anaesthesia:

Topical or “No-anaesthesia” techniques are not a good idea!!
– Iris manipulation

Regional block is sufficient: subtenons, peri or retro bulbar

Young adults: General anaesthesia

The Operation:

Type: Usually phacoemulsification “*There is no shame in doing an extracapsular cataract extraction*”.

Incision: Scleral tunnel with <1mm entry in cornea.

Superior or temporal: Possible future trabeculectomy.

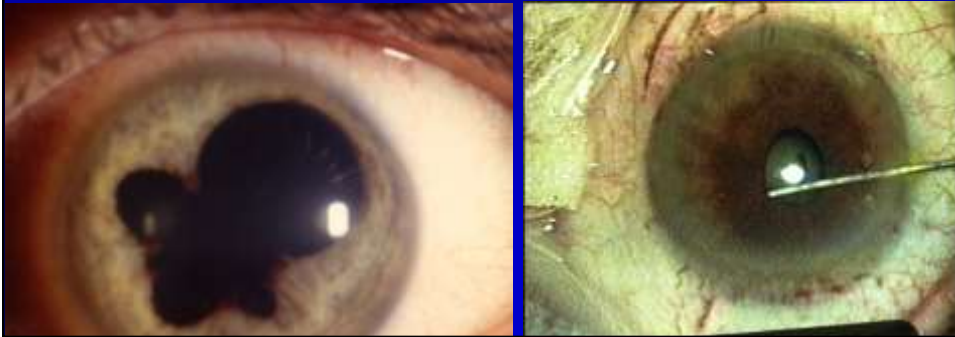
INTRA-OPERATIVE CONSIDERATIONS

Dispersive viscoelastic: Viscoat - soft shell

Excise any pupillary membrane

Synechiolysis: With blunt cannula and viscoelastic (through iridectomy). Vannas scissors

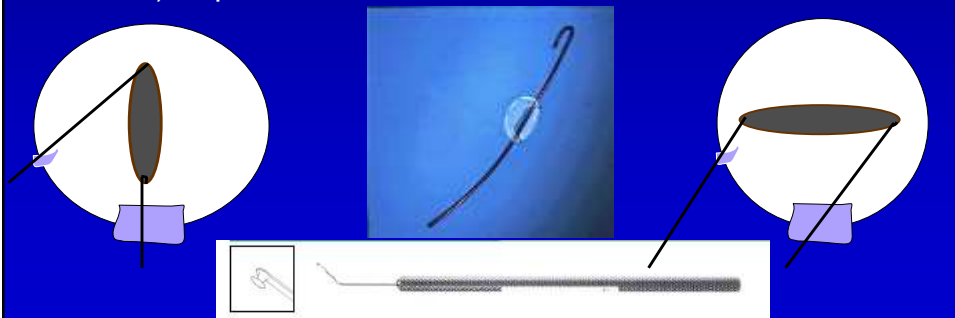
Possible peripheral iridectomy

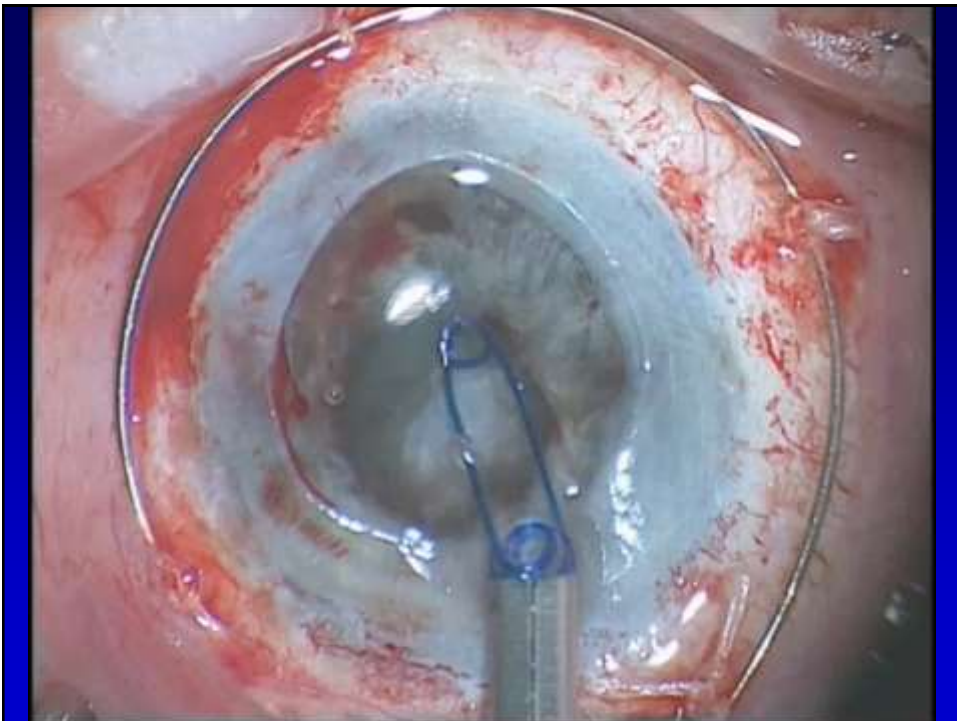
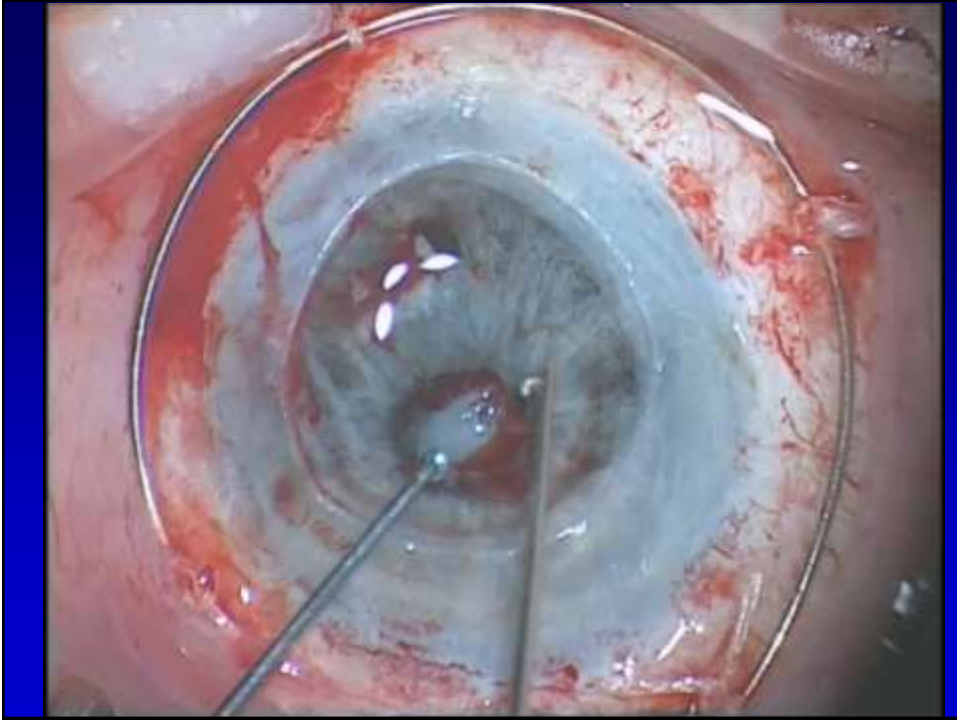


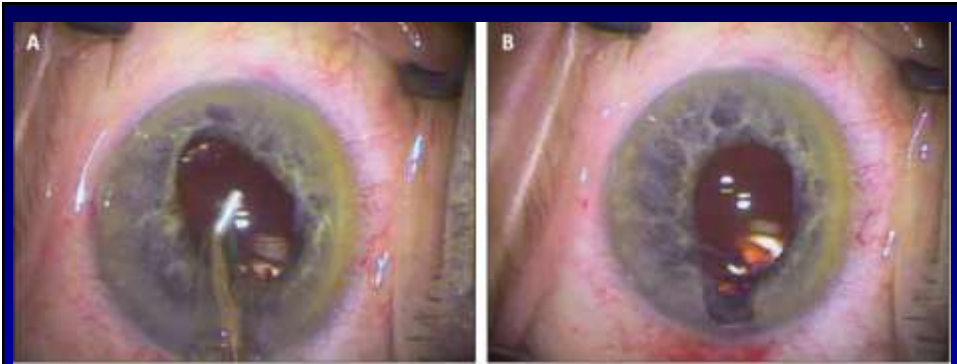
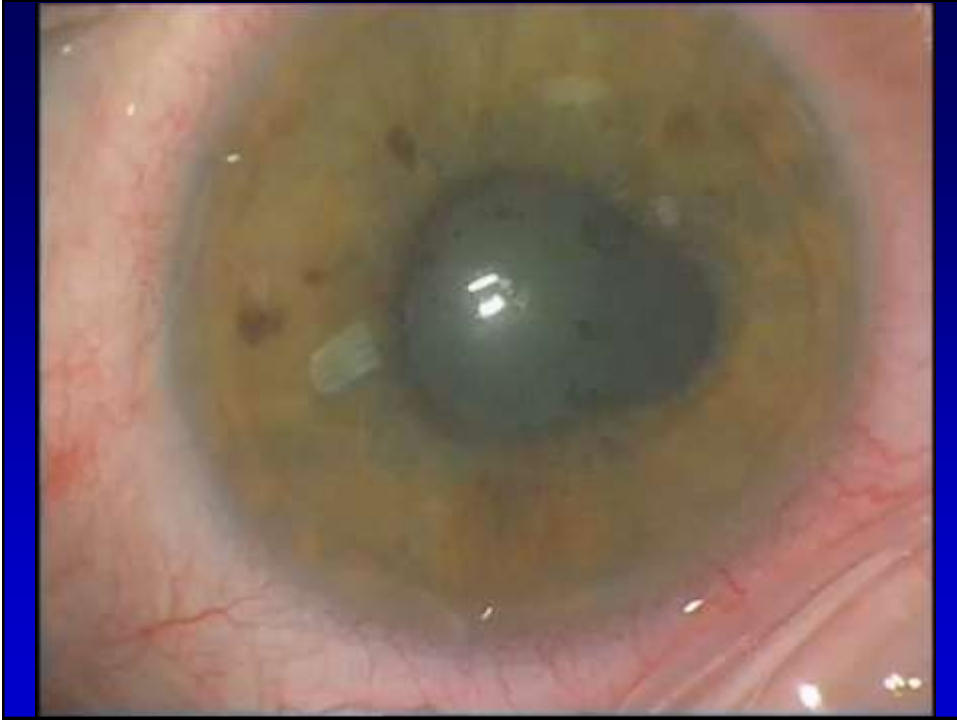INTRA-OPERATIVE CONSIDERATIONS

Pupil Dilation Strategies:

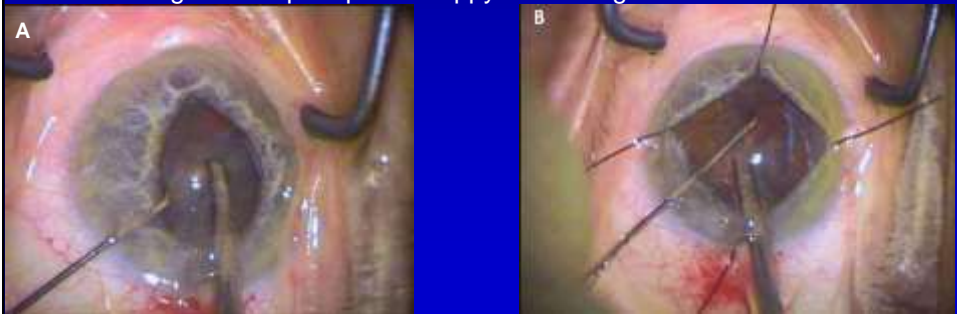
- Intensive medication including 10% phenylephrine and viscoelastic
- Stretching – risk of bleeding and permanent dilation
- Multiple sphincterotomies – risk as above
- Pupil dilation devices – iris hooks

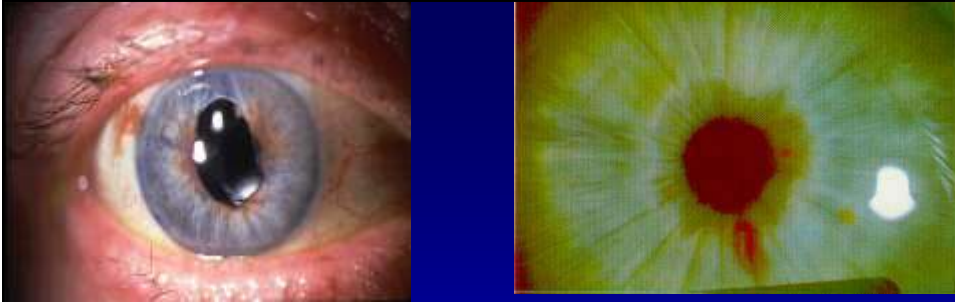




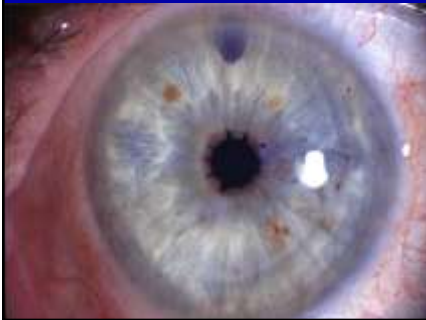
Iris billowing and iris prolapse of floppy iris managed with flexible iris hooks





Complications of pupil stretching: Pupil tear and haemorrhage

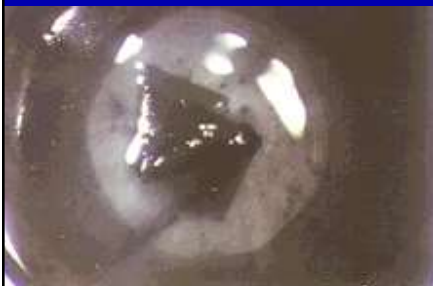

Multiple Sphincterotomies

INTRA-OPERATIVE CONSIDERATIONS

Capsulorehxis: Vision blue. Large is good. May need a can-opener capsulotomy.

Hydrodissection: Gentle. Be aware of posterior capsule dehiscence.



INTRA-OPERATIVE CONSIDERATIONS

Phacoemulsification: Low flow low power. Suction of soft nucleus. Adjust bottle height according to Chamber depth.

Irrigation aspiration: Low flow. Avoid fluid jet on endothelium.

IOL insertion: Use Cohesive viscoelastic.

Implant: ?Avoid in children with JRA, Sarcoid uveitis, VKH

Heparin coated PMMA or acrylic.

Avoid silicone lenses.

Avoid sutured PC IOL or AC IOLs.

Wound closure: Anticipate poor healing because of steroid use. Low threshold for placing a stitch.

POST-OPERATIVE CONSIDERATIONS

Post-operative medication:

Steroids: Intensive topical steroids and/or Oral steroids. Intravenous methyl prednisolone especially if acute fibrinous reaction. Periocular steroids or intravitreal steroids

Diamox

Mydriatics

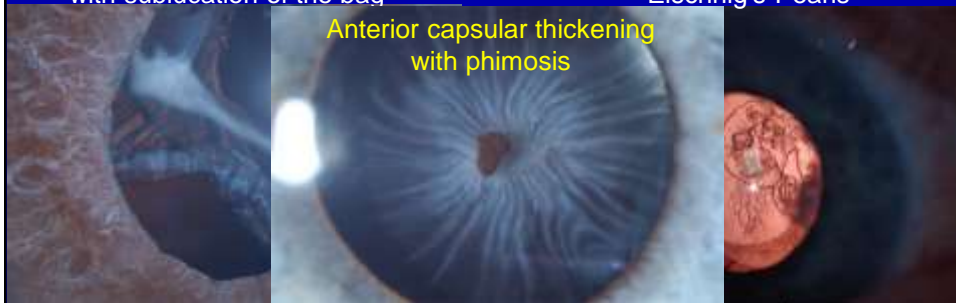- Fibrinous exudate: Recombinant tissue plasminogen activator (rtPA)
- CME: Intensive topical steroids and non steroidal

POST-OPERATIVE COMPLICATIONS

- Anterior uveitis, cyclitis membrane and adhesions
- Cyclitis with hypotony
- Glaucoma
- Posterior capsule thickening: YAG risk of CME
- CME

Posterior capsular thickening
with subluxation of the bag

Posterior capsular thickening
Elschnig's Pearls



PRINCIPLES

- The longer the eye is quiet preoperatively the better the outcome. At least three months
- Perform surgery early in the course of the disease if protracted disease is expected
- Vigorous post operative control of inflammation is paramount
- Minimal iris handling
- Poor Predictors of Cataract surgery outcome:
 1. Young age
 2. Extensive posterior synechiae
 3. Hypotony or glaucoma
 4. Previous poor outcome from other eye surgery
 5. Generally cataract with posterior uveitis does better than with anterior uveitis



THANK YOU