

TRIFOCAL TORIC IOL Premium Complication

Dr. Nabil Ragaï Kamel

Head of The Department of Ophthalmology
Quironsalud San jose Hospital –Madrid
Quironsalud Marbella Hospital- Marbella
Universidad Europea de Madrid
SPAIN

Dr. Alfonso Arias Puente

Jefe de Servicio de Oftalmología
Profesor Titular de Oftalmología
UNIVERSIDAD REY JUAN CARLOS

TRIFOCAL TORIC IOL

Clinical Case

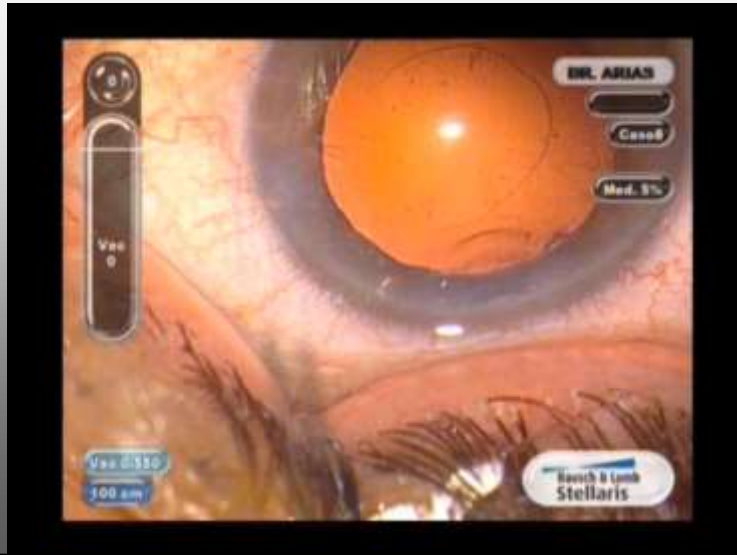
- 59 years old, driver, poor vision with spectacles, Presbyopia
- OD: +4.00 sph – 4,50 cil 5° BCVA: 0,6
- OI: +2,75 sph – 1,75 cil 40° BCVA: 0,7
- Crystalline lens: Nuclear Cataract ++
- Endotelial cell count : OD: 2.850 cel / mm² OI: 2.753 cel / mm²
- Macular OCT : Normal

Surgical Option
AT-LISA TRI TÓRIC



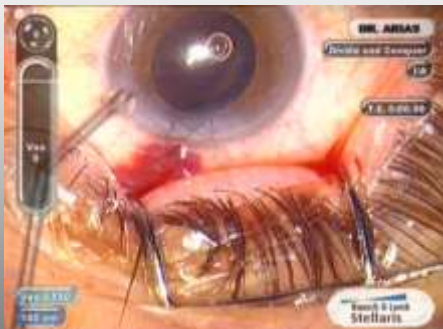TRIFOCAL TORIC IOL

OD (14-may-2014)

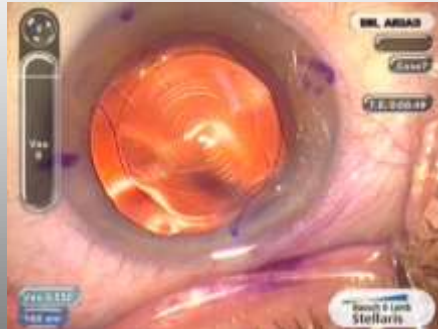

TRIFOCAL TORIC IOL

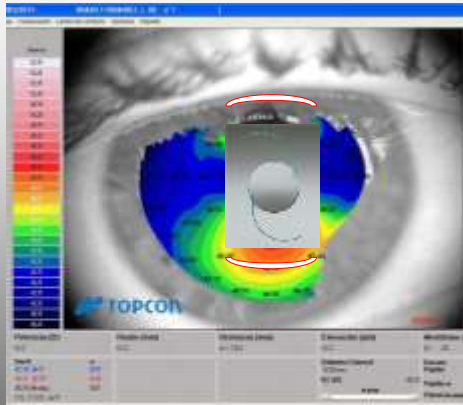
Surgery OD (14-mayo-2014)



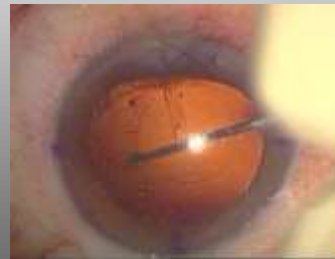Surgery OI (21-mayo-2014)



Postop OD (28-may-2014)

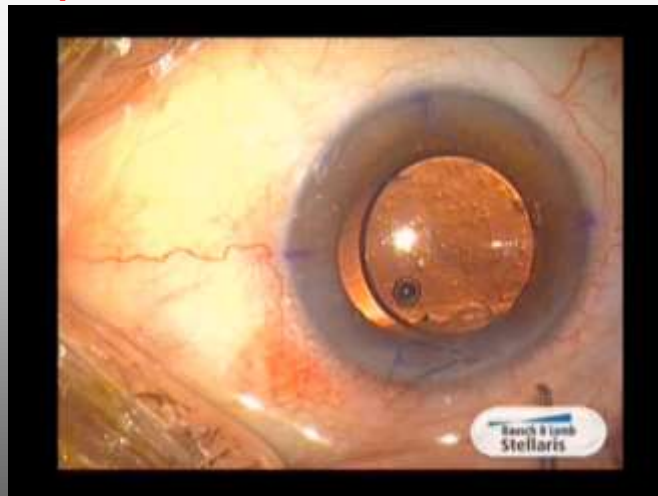


Sim-K	e
42.18 @ 5°	0.57
49.31 @ 95°	0.46
45.74 (Media)	0.51
CYL -7,13 D ax 5°	



REFRACCIÓN: +13,00 sph - 6,50 cil 0° BCVA : 0,4

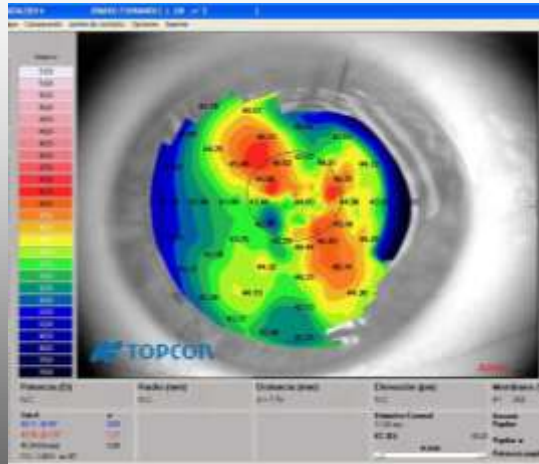
IOL Implantation (29-may-2014)



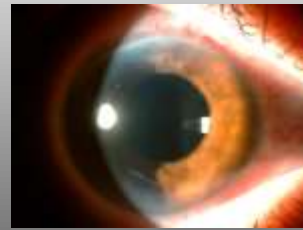
REFRACCIÓN: +13,00 sf - 6,50 cil 0° BCVA : 0,4

TRIFOCAL TORIC IOL

Postop OD (16- june -2014)



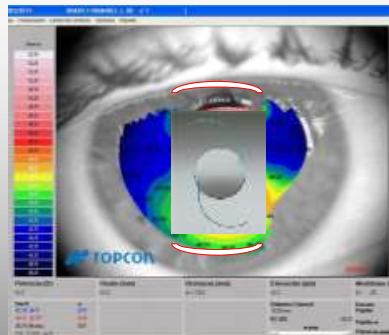
Sim-K	e
44,11 @ 45°	0,69
45,98 @ 135°	1,27
45,04 (Media)	0,98
CYL -1,86 D ax 45°	



REFRACCIÓN: -0.50 sph- 1,50 cil 20° BCVA : 0,8

TRIFOCAL TORIC IOL

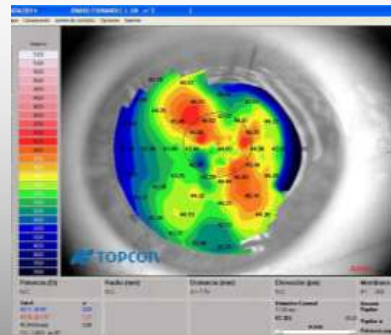
28- may -2014



Sim-K	e
42,18 @ 5°	0,57
49,31 @ 95°	0,46
45,74 (Media)	0,51
CYL -7,13 D ax 5°	

+13,00 sph - 6,50 cil 0° BCVA : 0,4

16- june -2014



Sim-K	e
44,11 @ 45°	0,69
45,98 @ 135°	1,27
45,04 (Media)	0,98
CYL -1,86 D ax 45°	

-0.50 sph - 1,50 cil 20° BCVA : 0,8

Muchas Gracias

