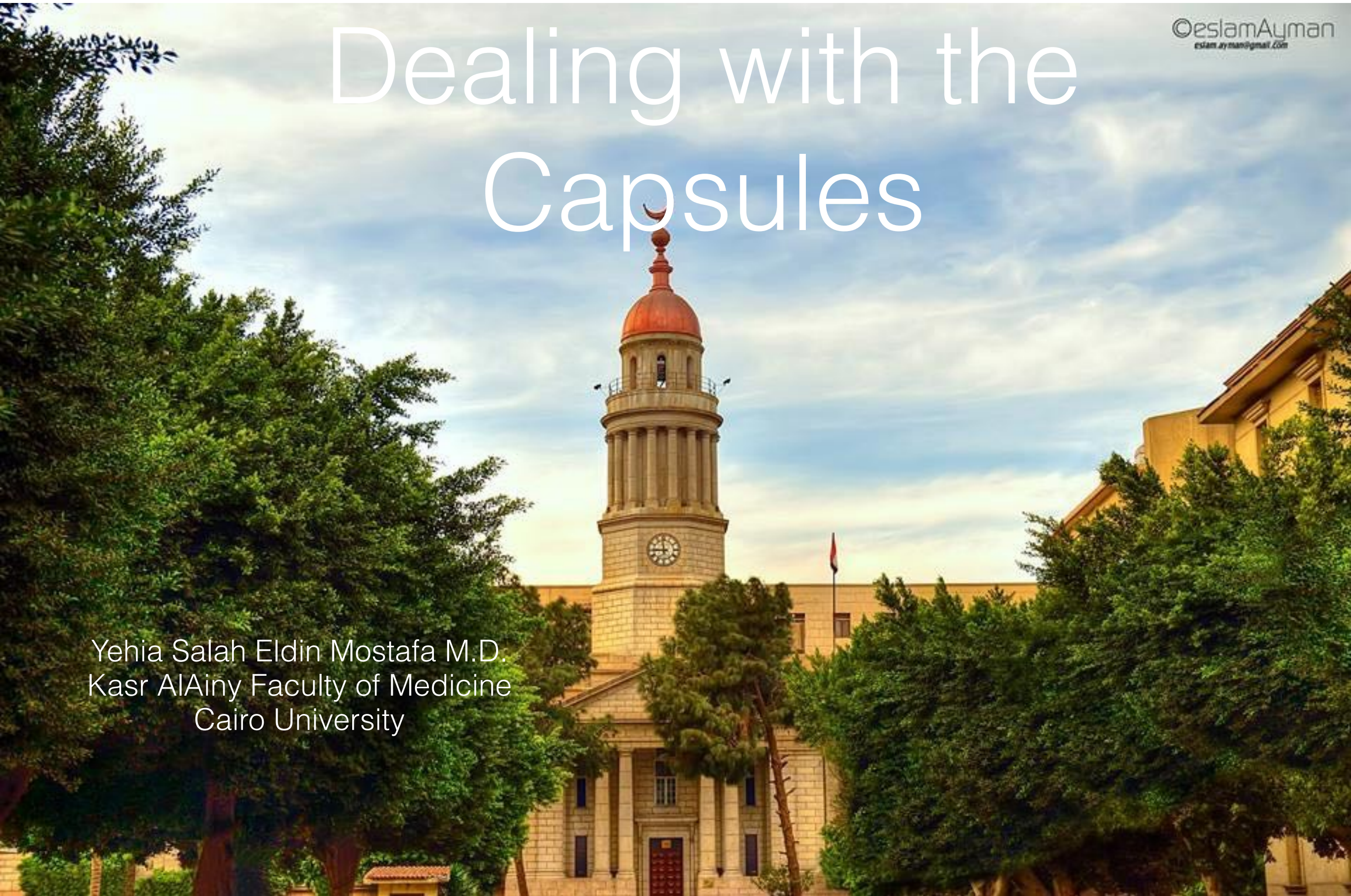


Dealing with the Capsules

©eslamAyman
eslam.ayman@gmail.com

Yehia Salah Eldin Mostafa M.D.
Kasr AlAiny Faculty of Medicine
Cairo University




11-16 mic

increase with age

thickest 13.5-16 mic

Thinnest 7 mic



Crystalline lens

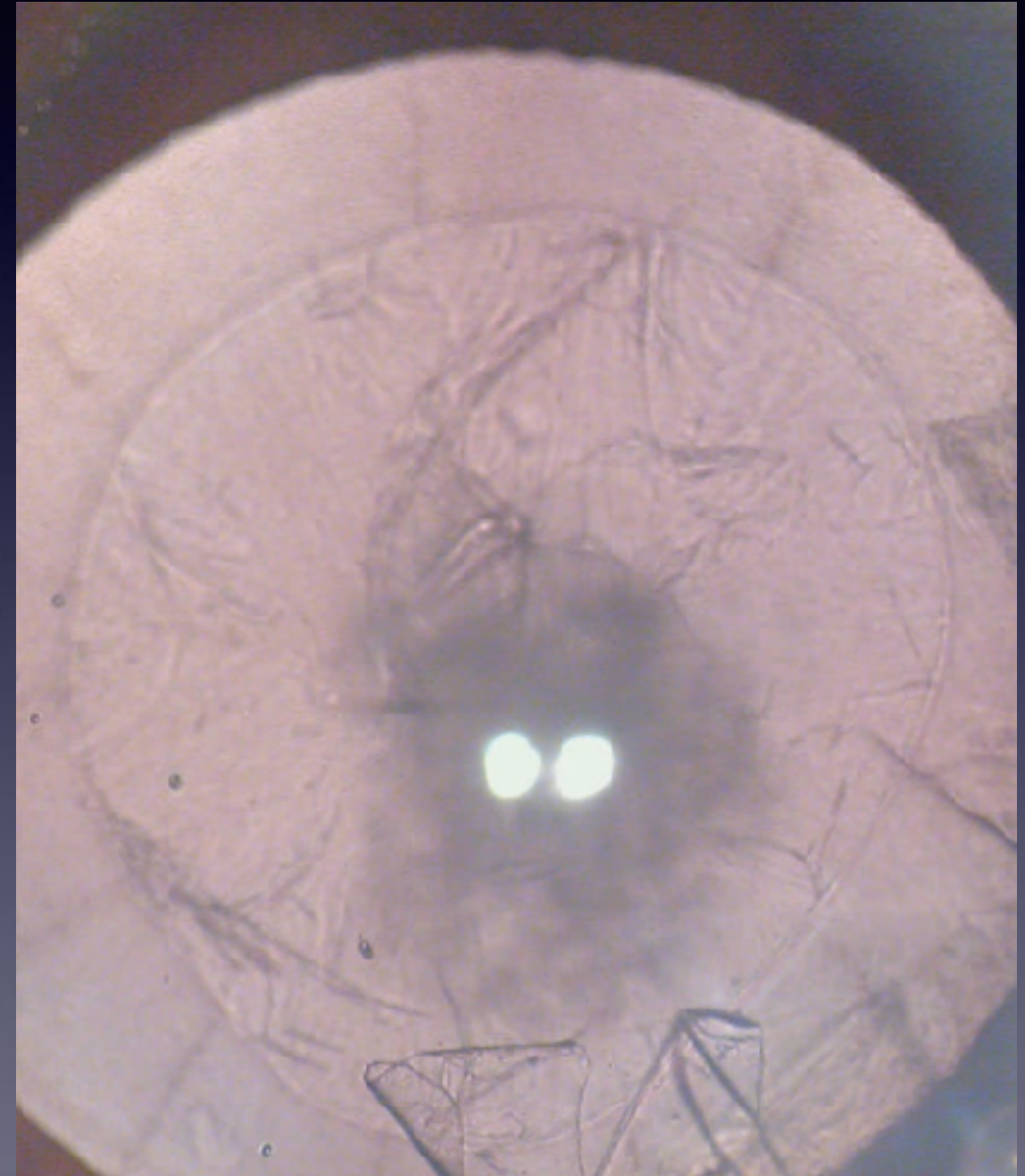


9-7 mic decrease with age

3.5 mic

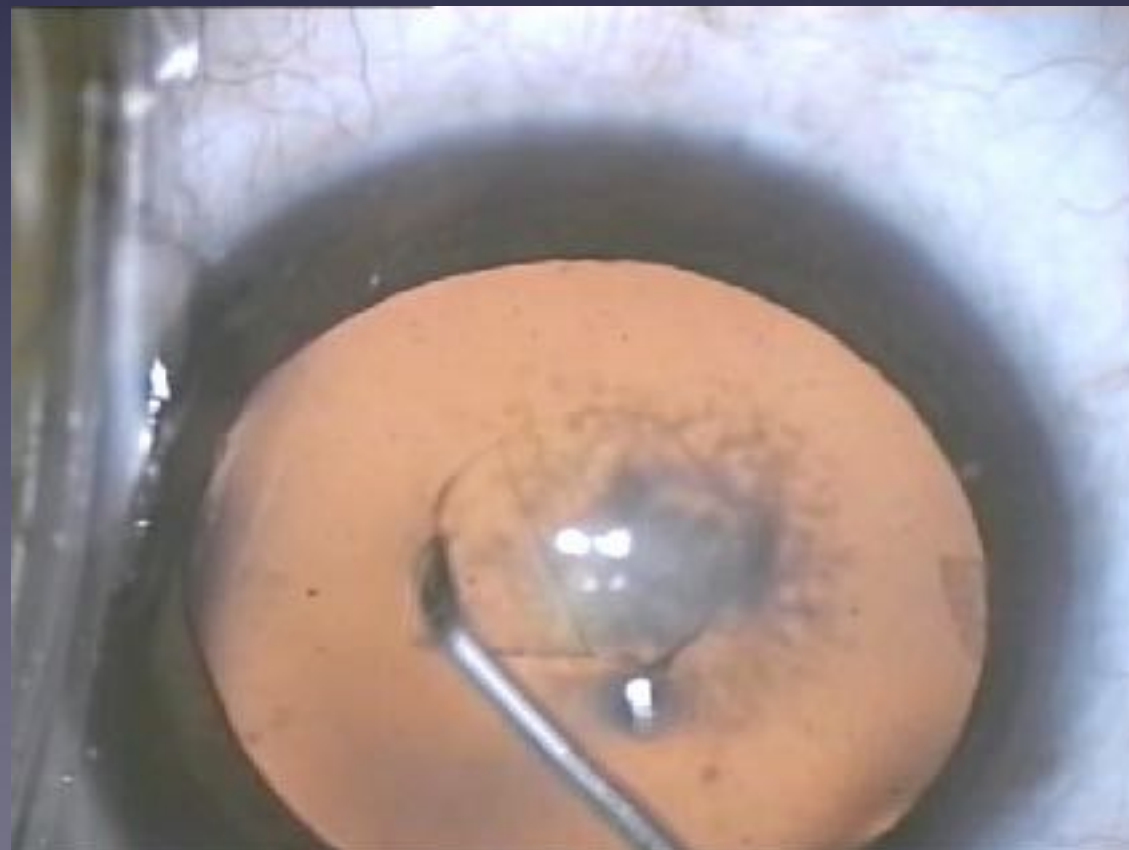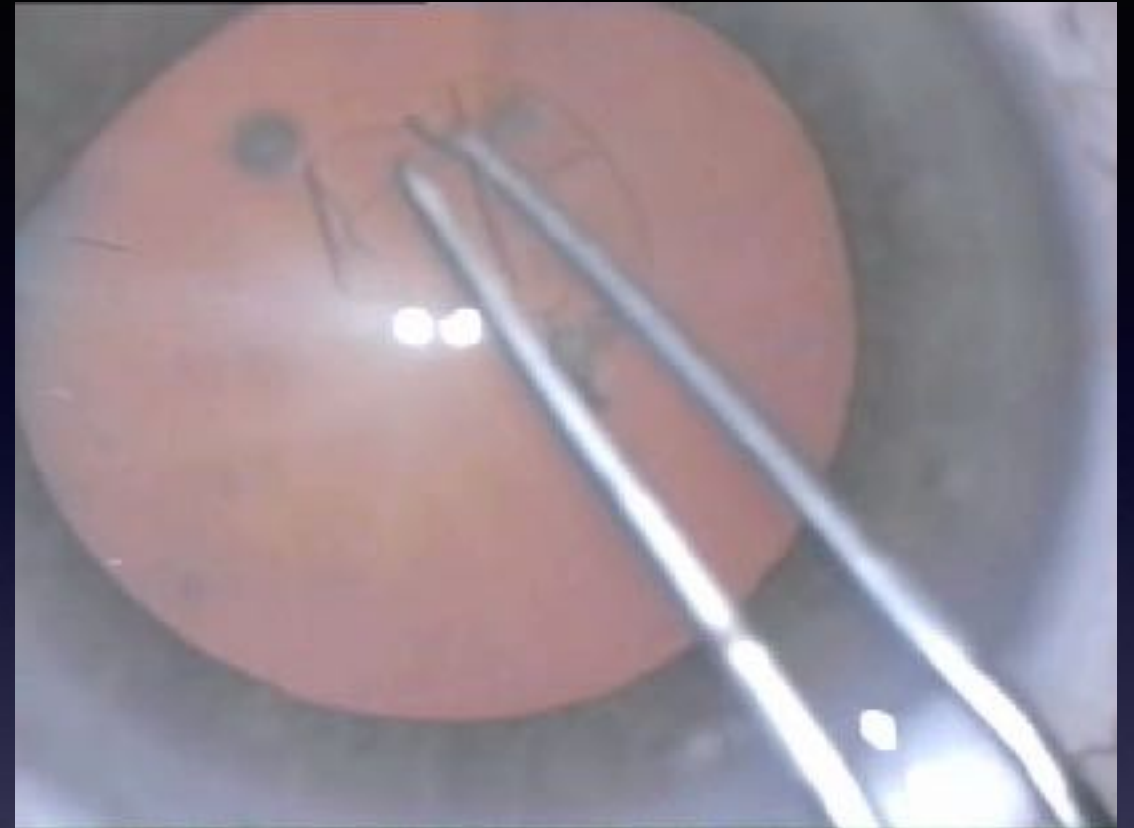
The Capsule

- **We need to learn about it**
- **Feel it**
- **For better and safer surgery**
- **For better complication management**



Capsulorhexis

- FORCEPS
- NEEDLE
- FEMTO



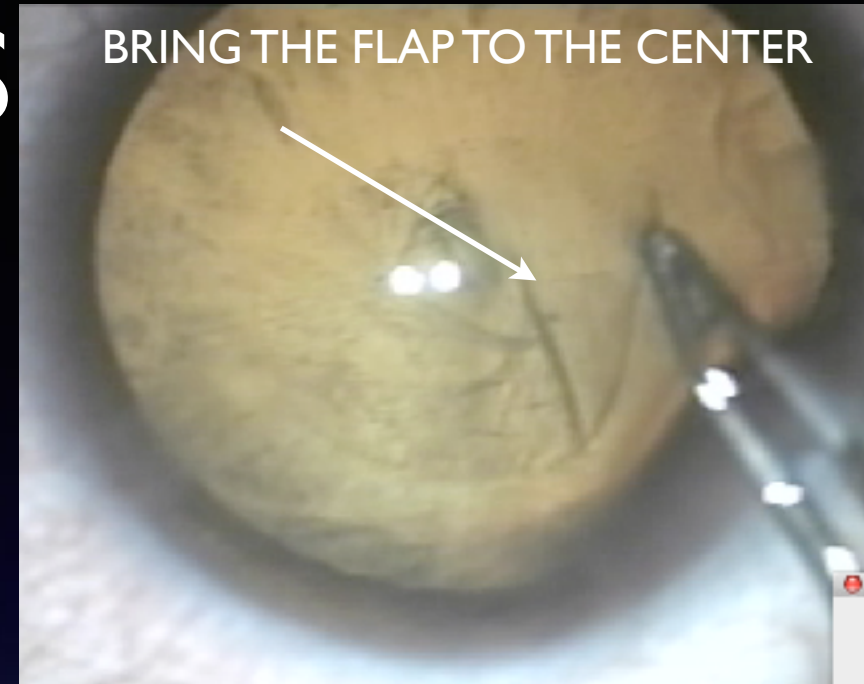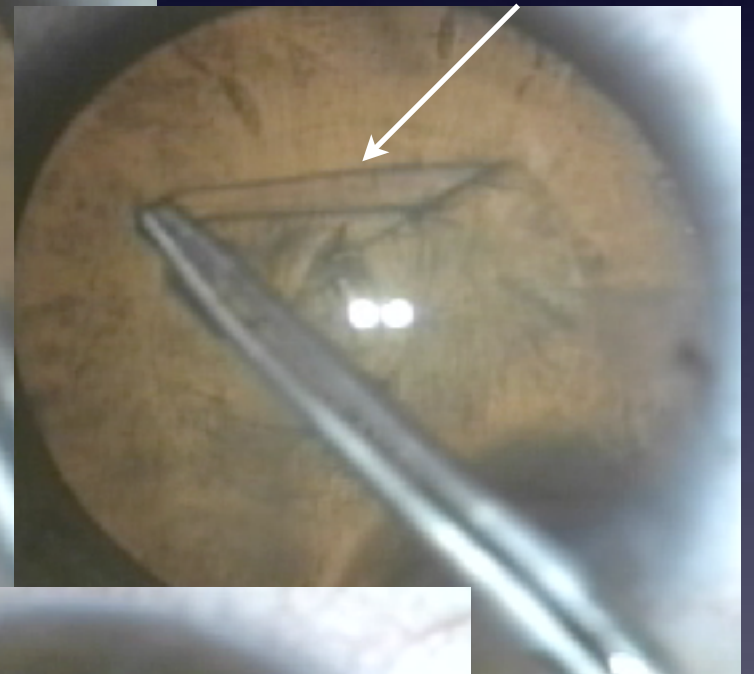

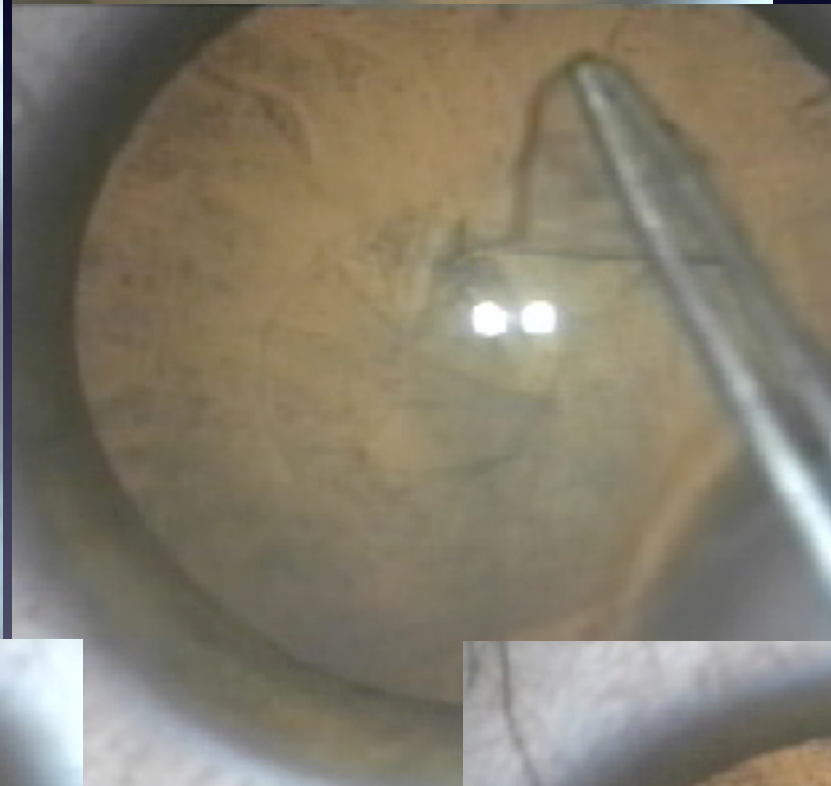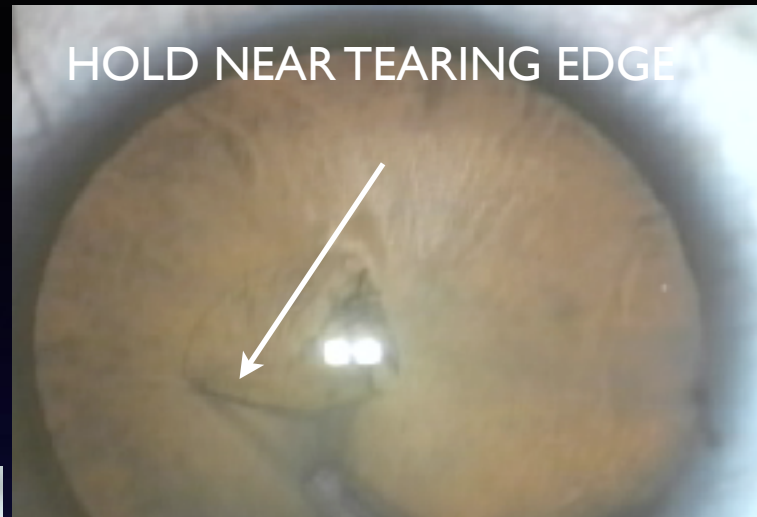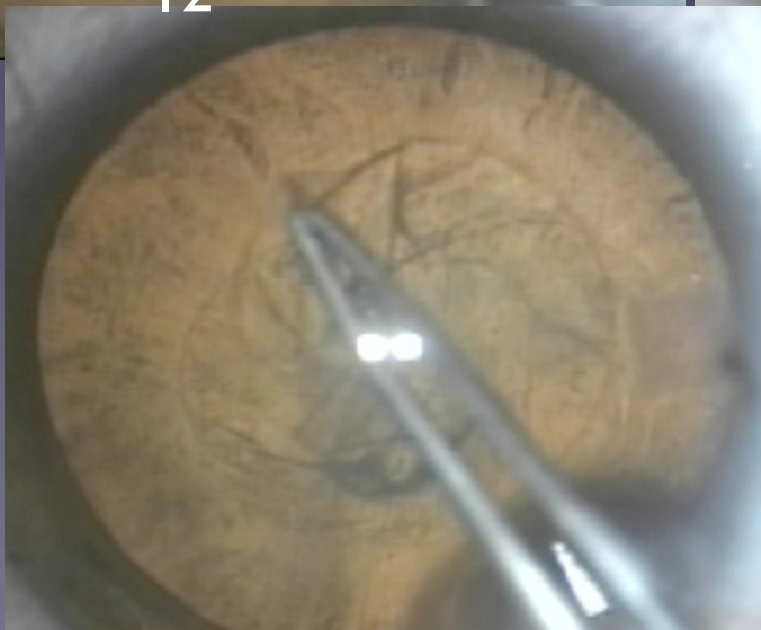4 GOLDEN RULES

DEEP AC

HOLD NEAR TEARING EDGE

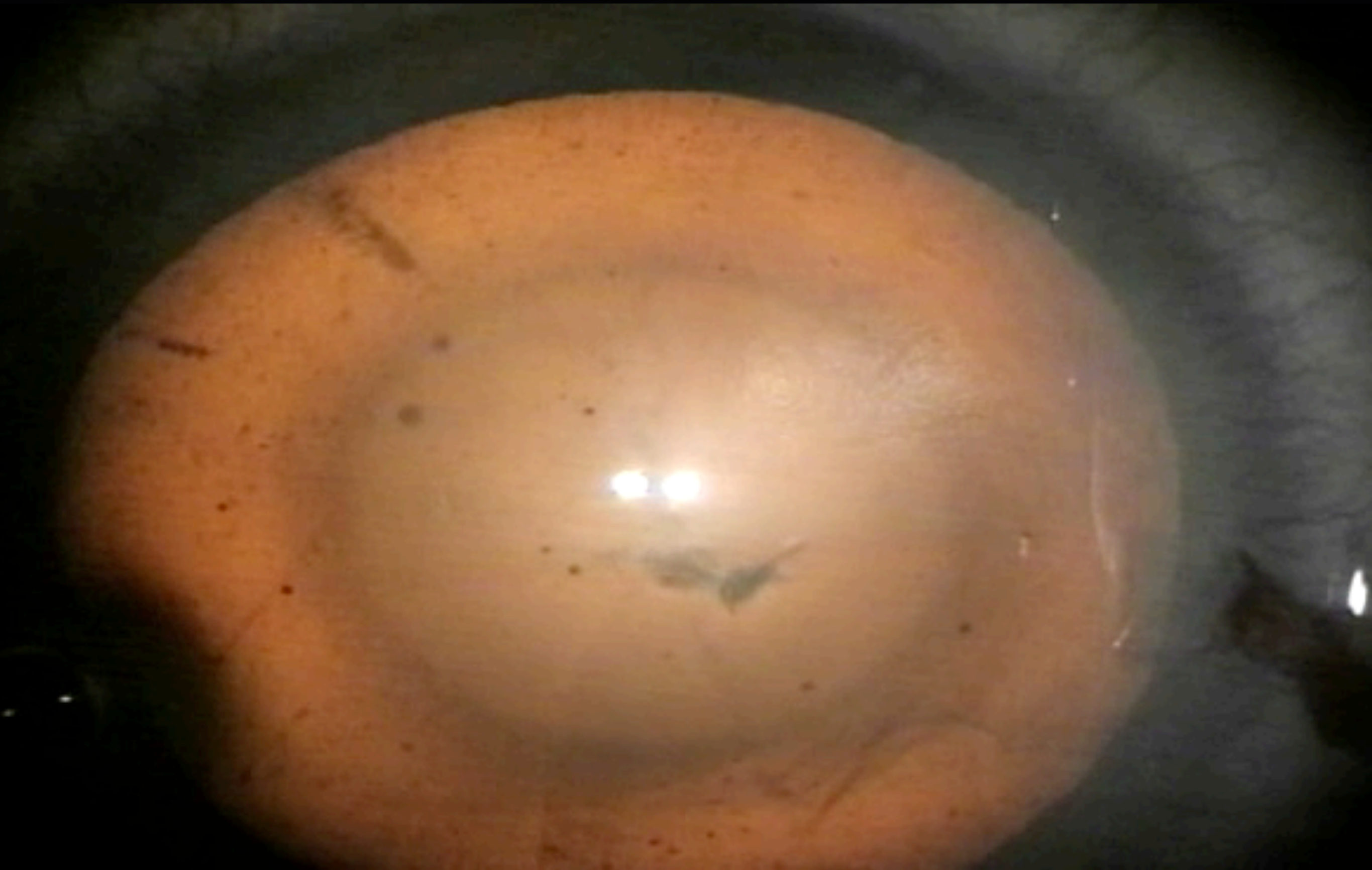
BRING THE FLAP TO THE CENTER

MOVE EVERY 2 CLOCK HOURS

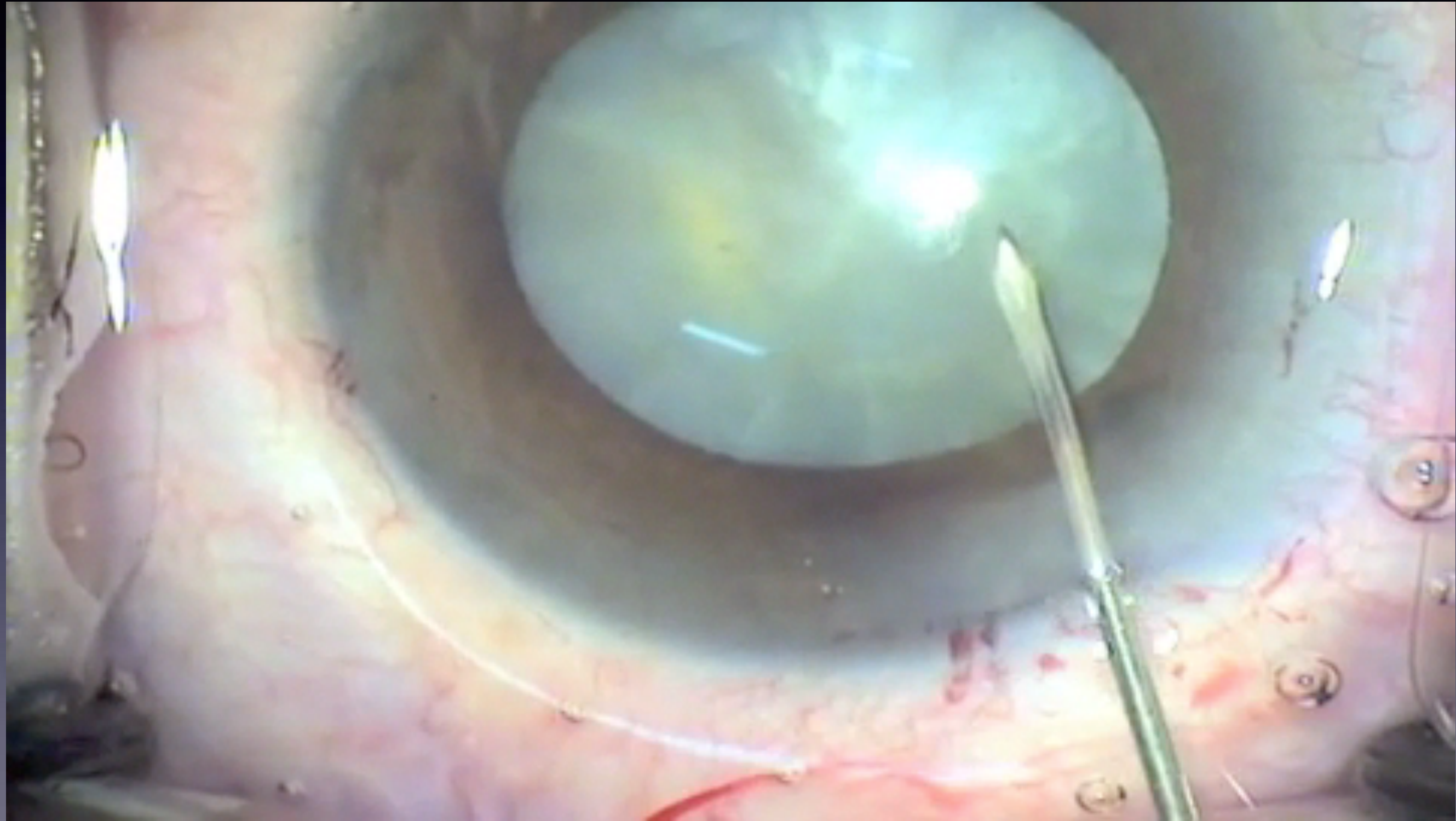




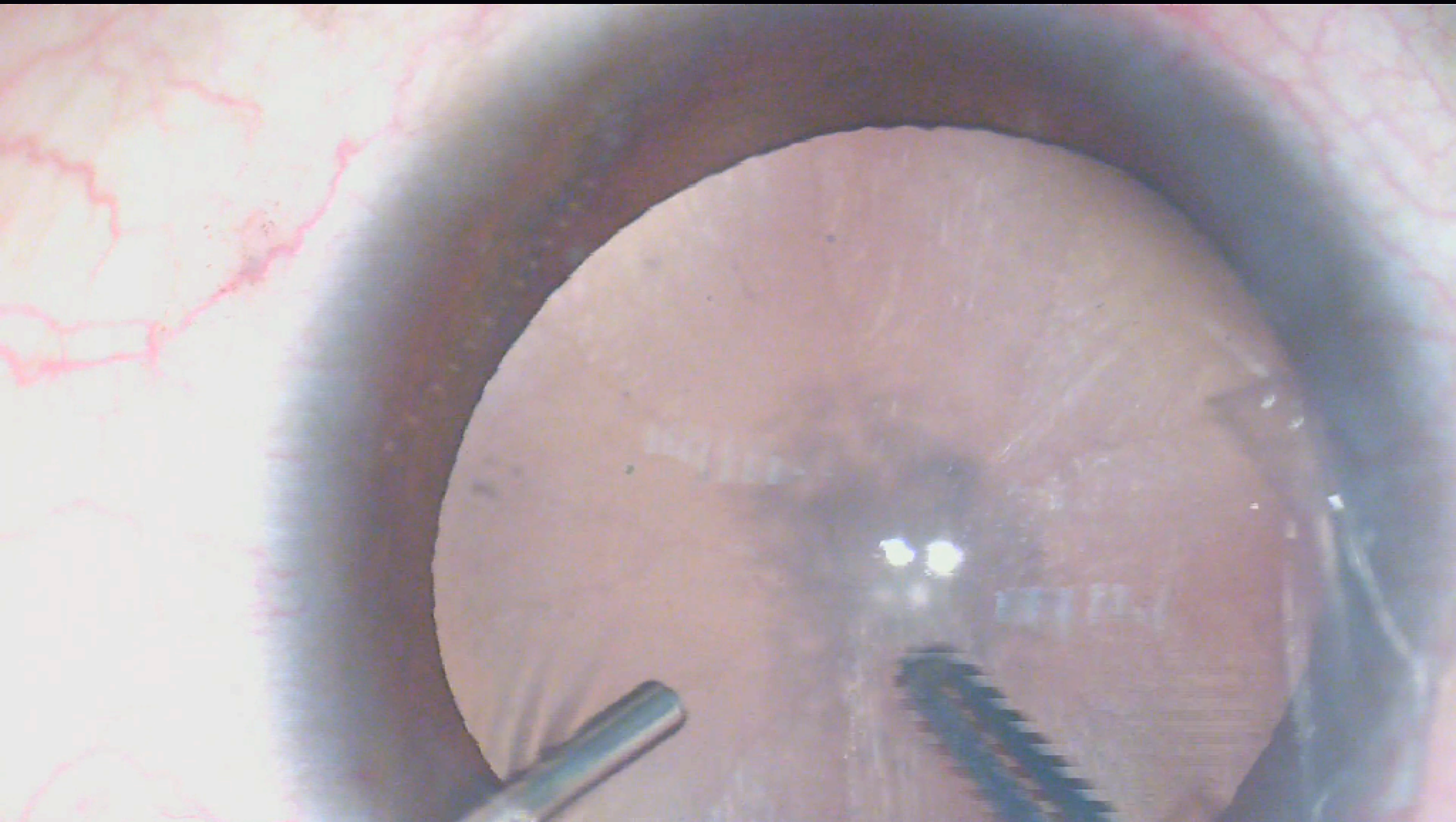
IDEAL RHEXIS FORCEPS



Intumescent Cataract

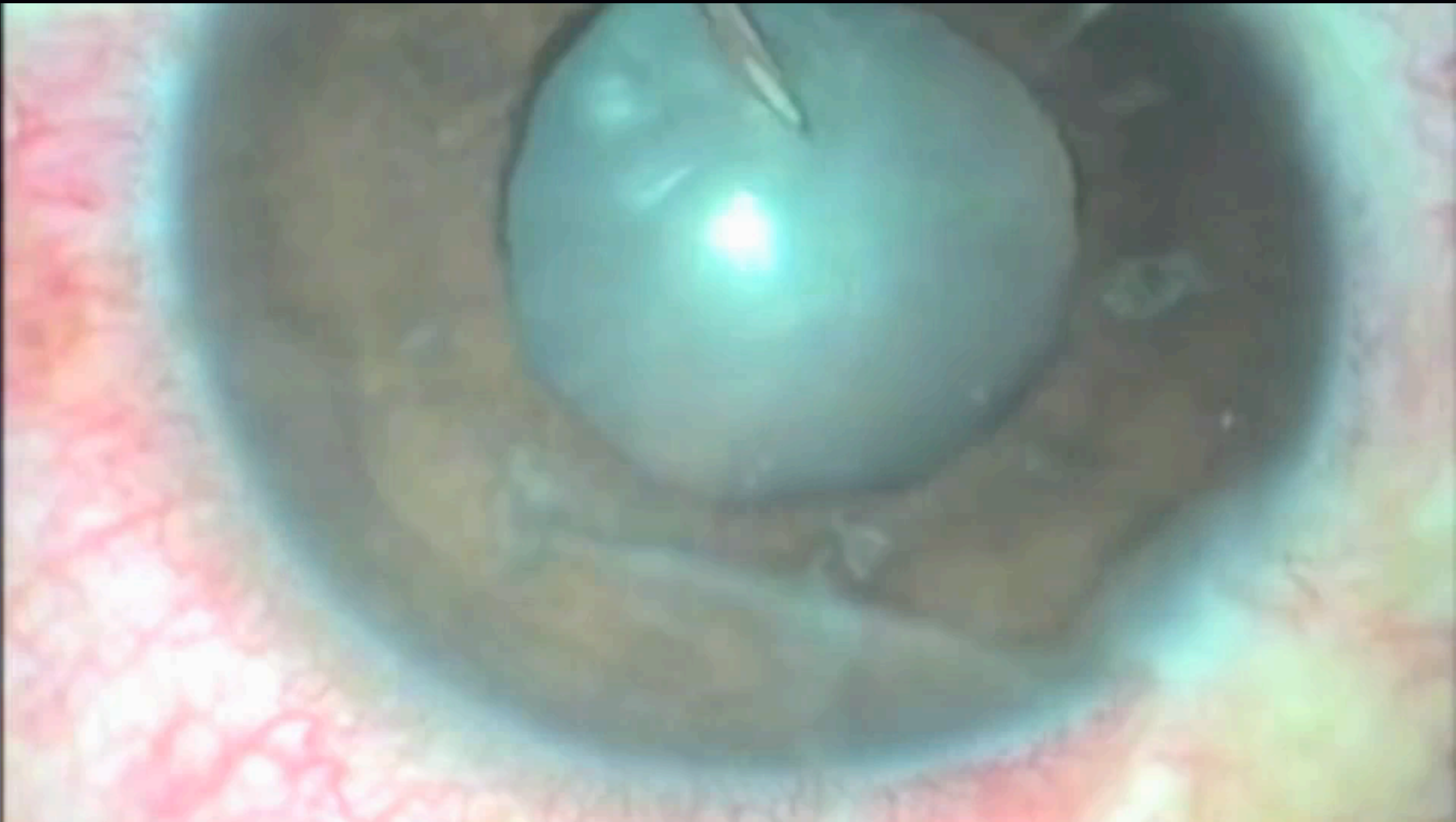


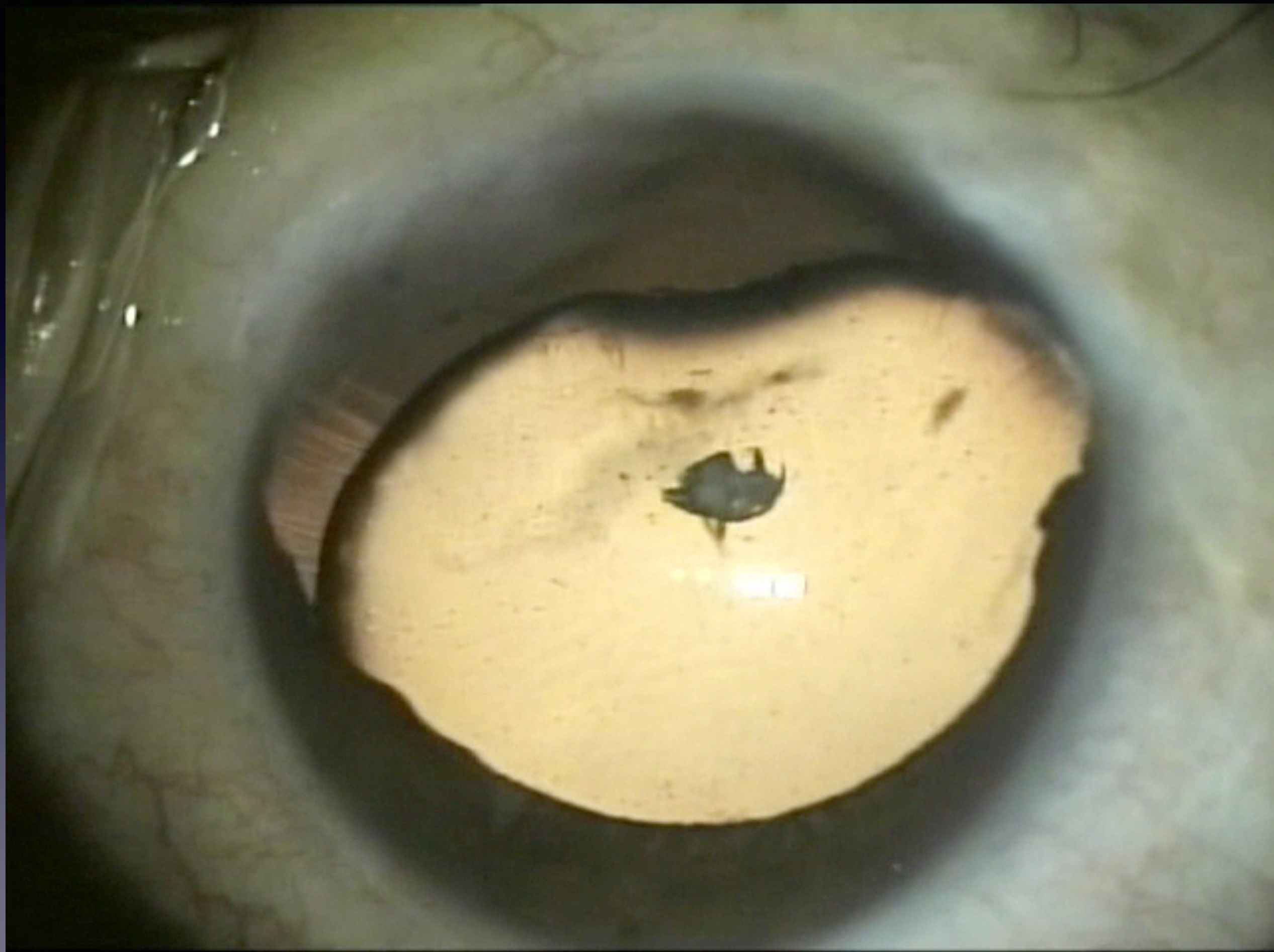
PEDIATRIC

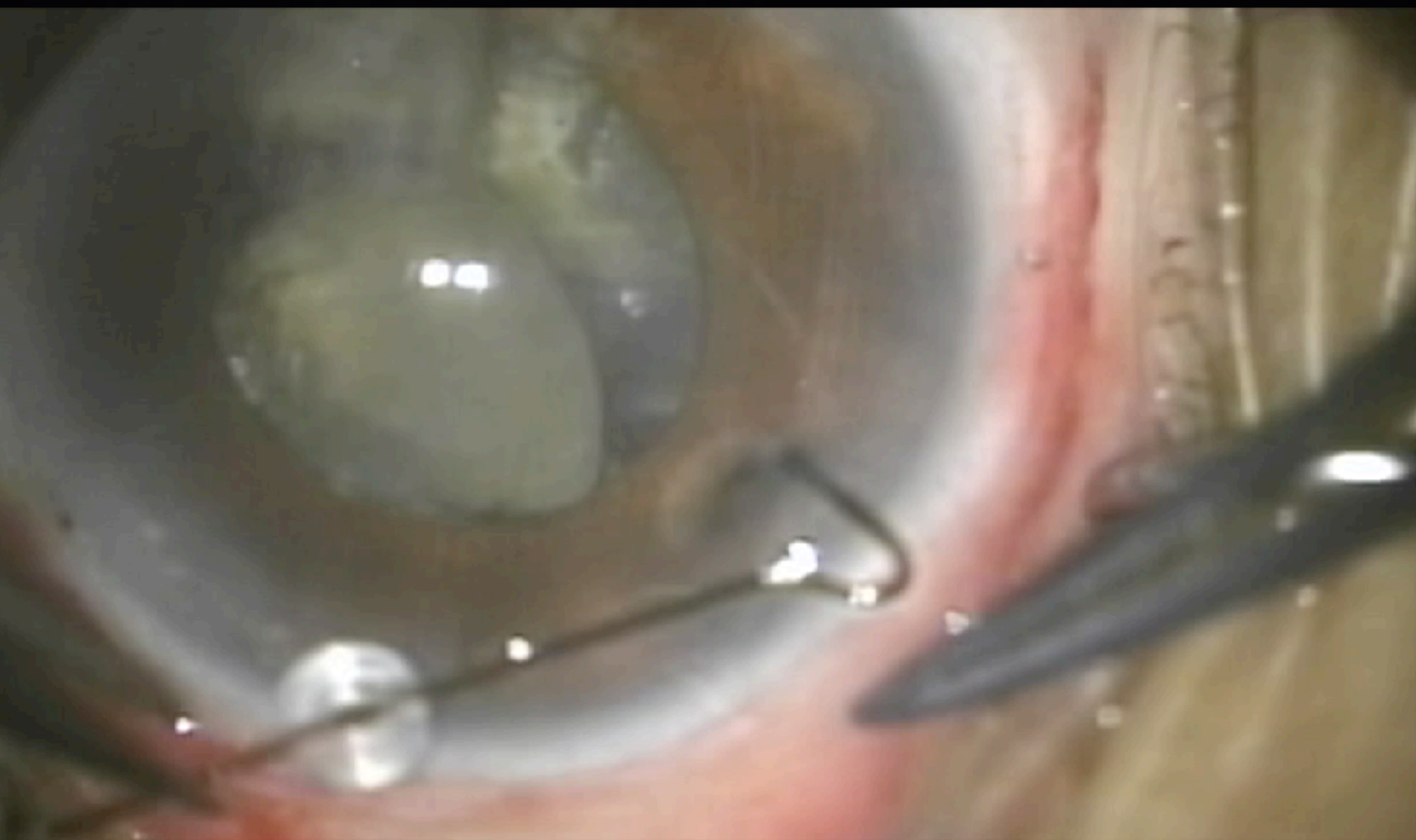




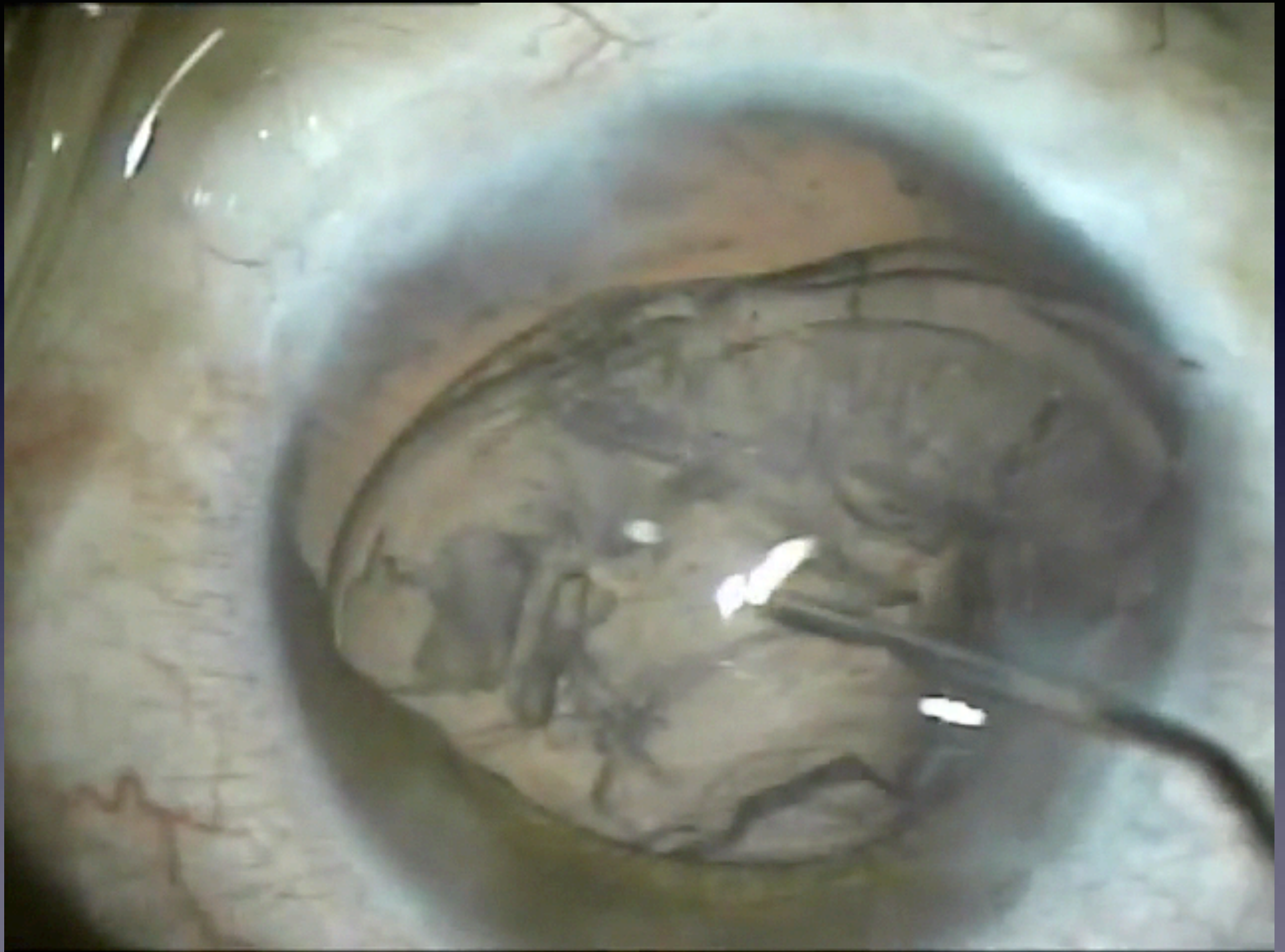
SUBLUXATION



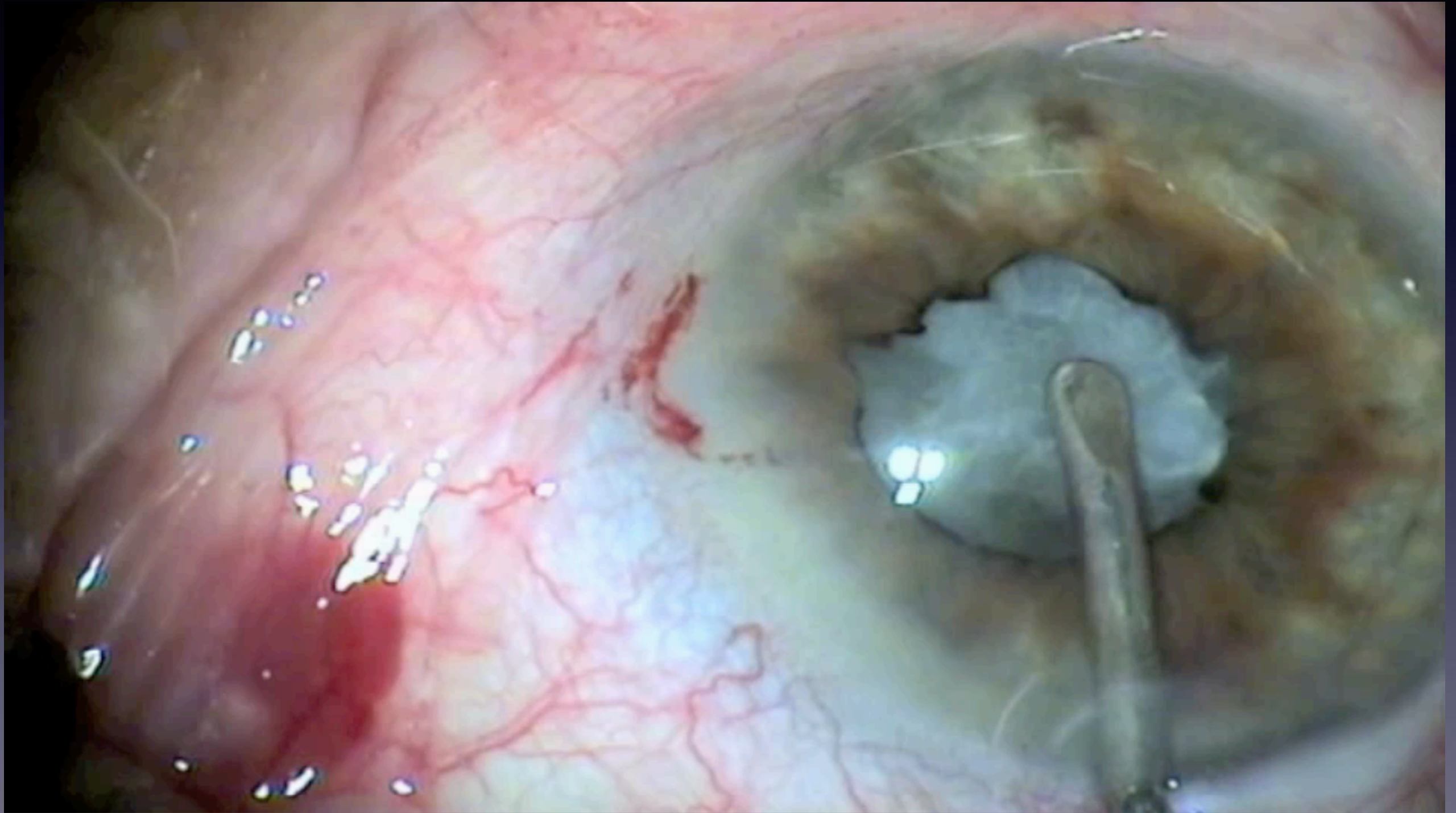




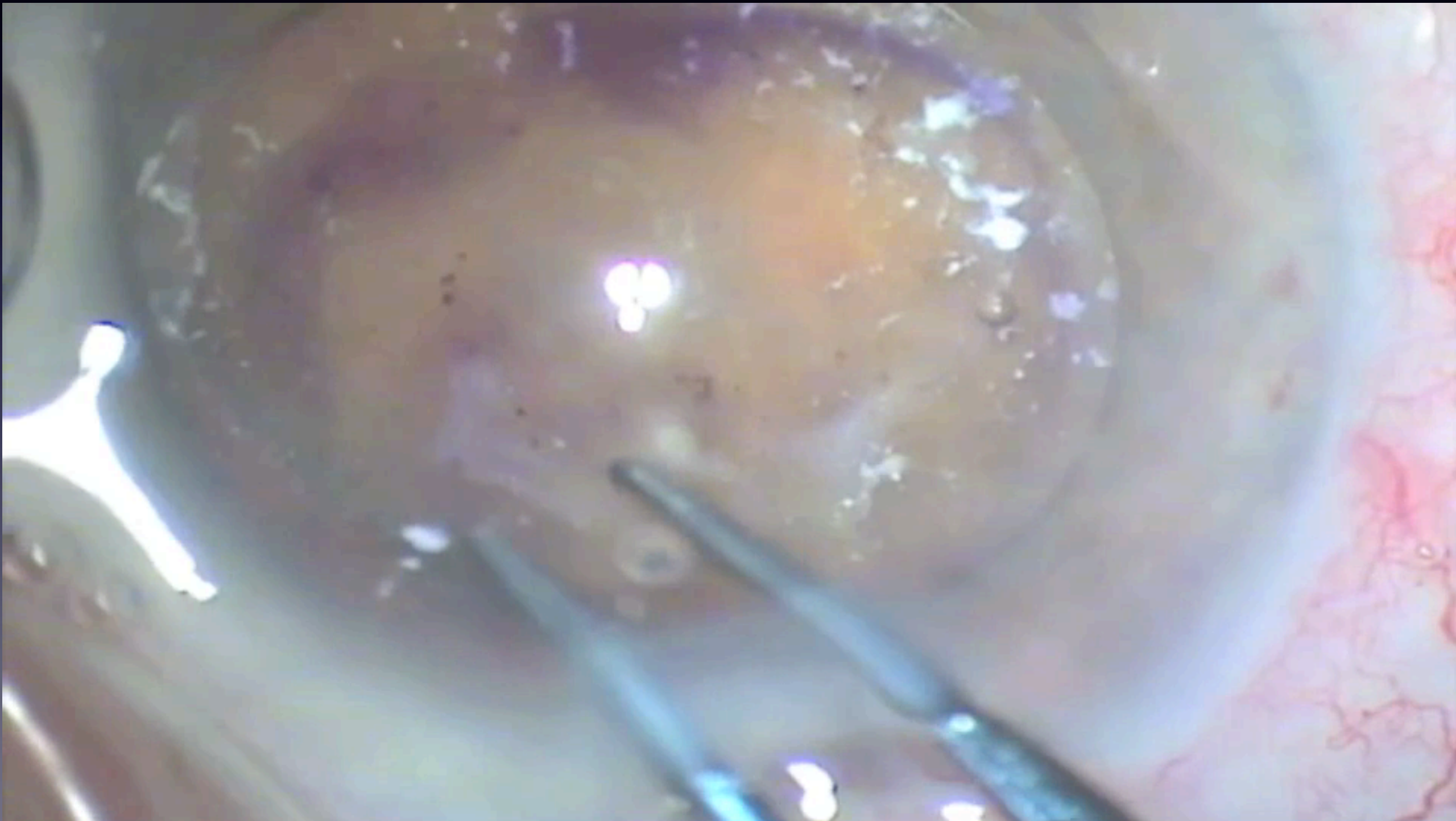
CAPSULE TENSION RING



Hypermaturation Cataract-miotic

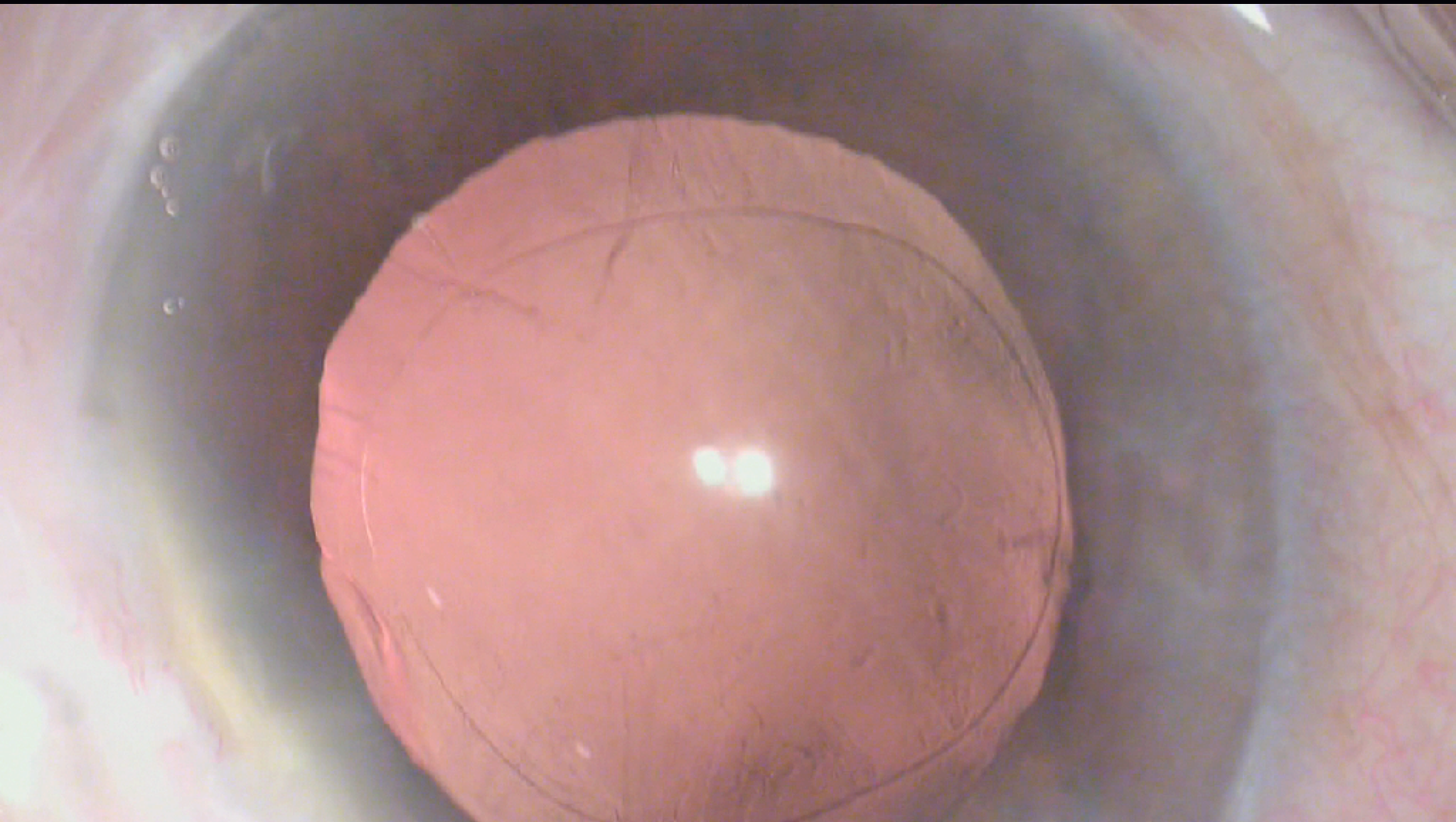


Subluxation -Hypermature

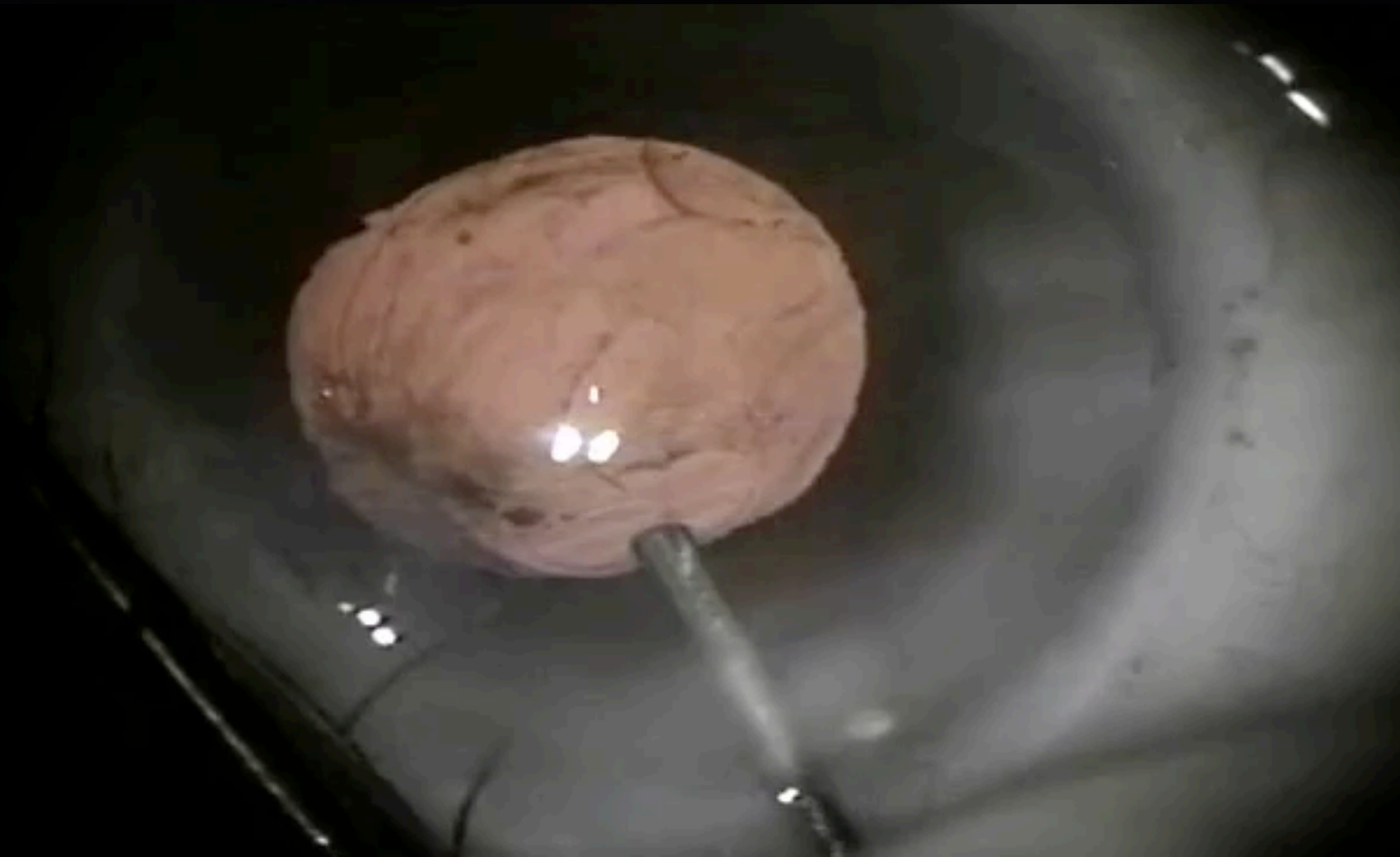



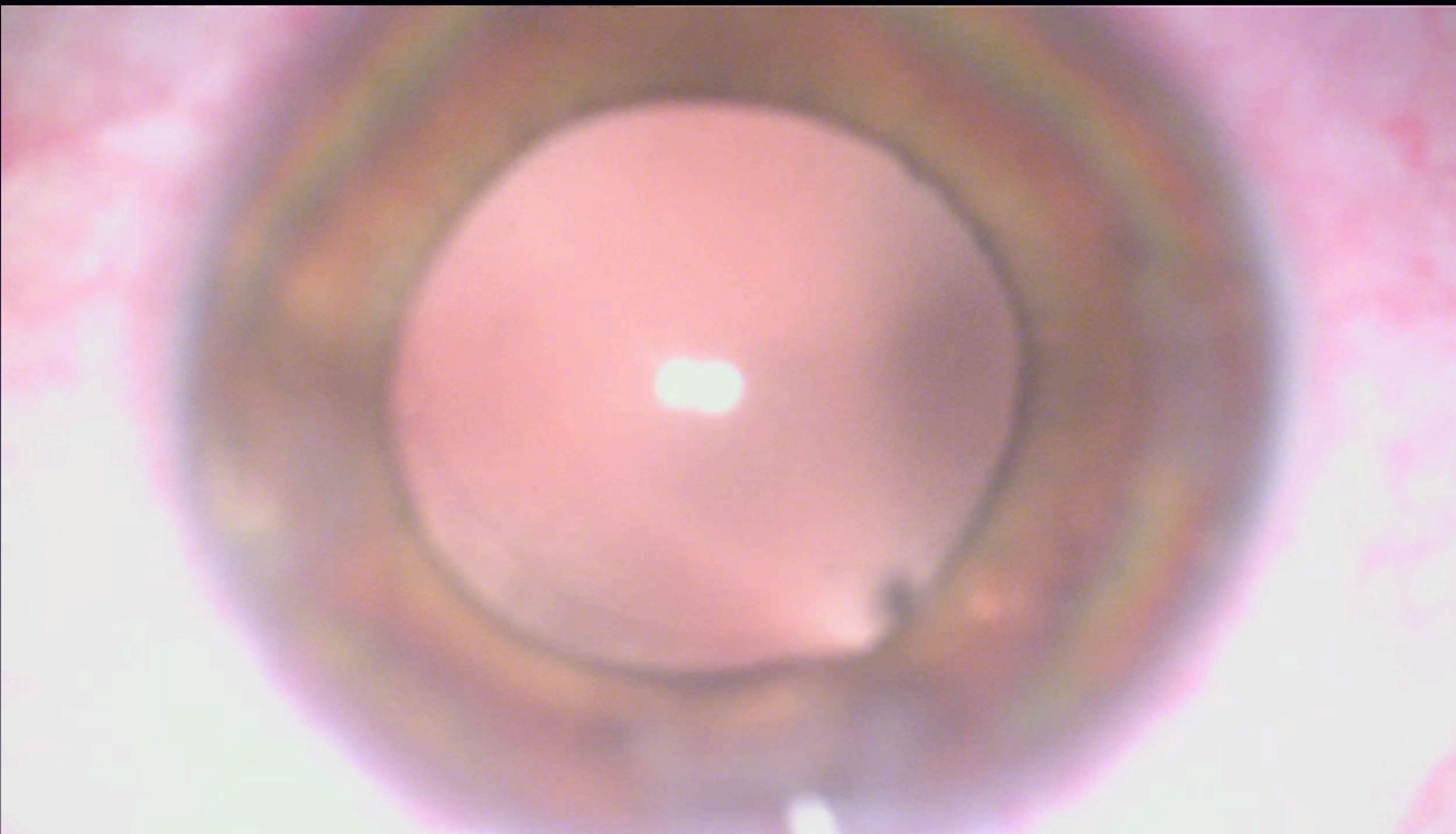
Washing posterior capsule



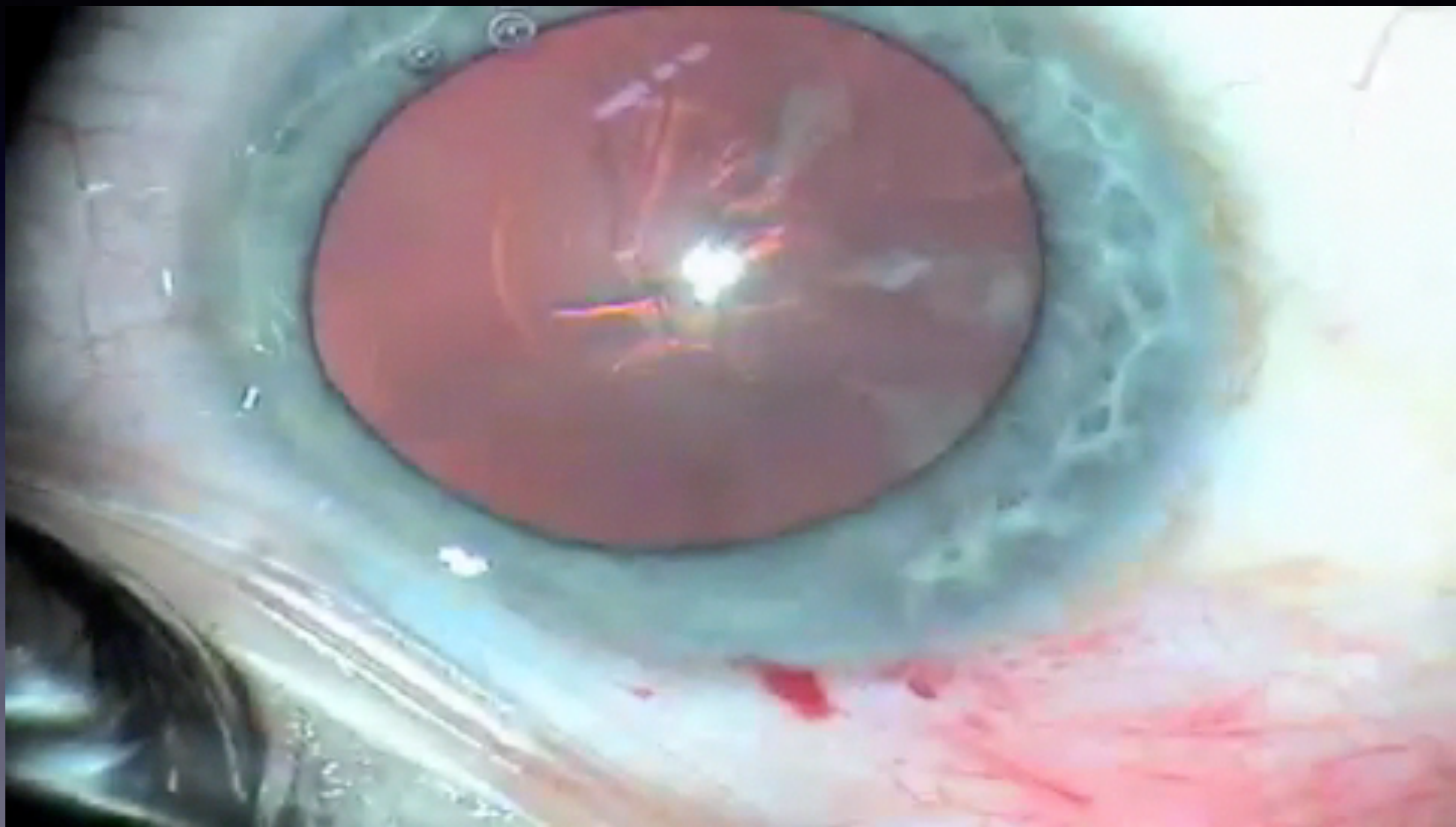
PEELING



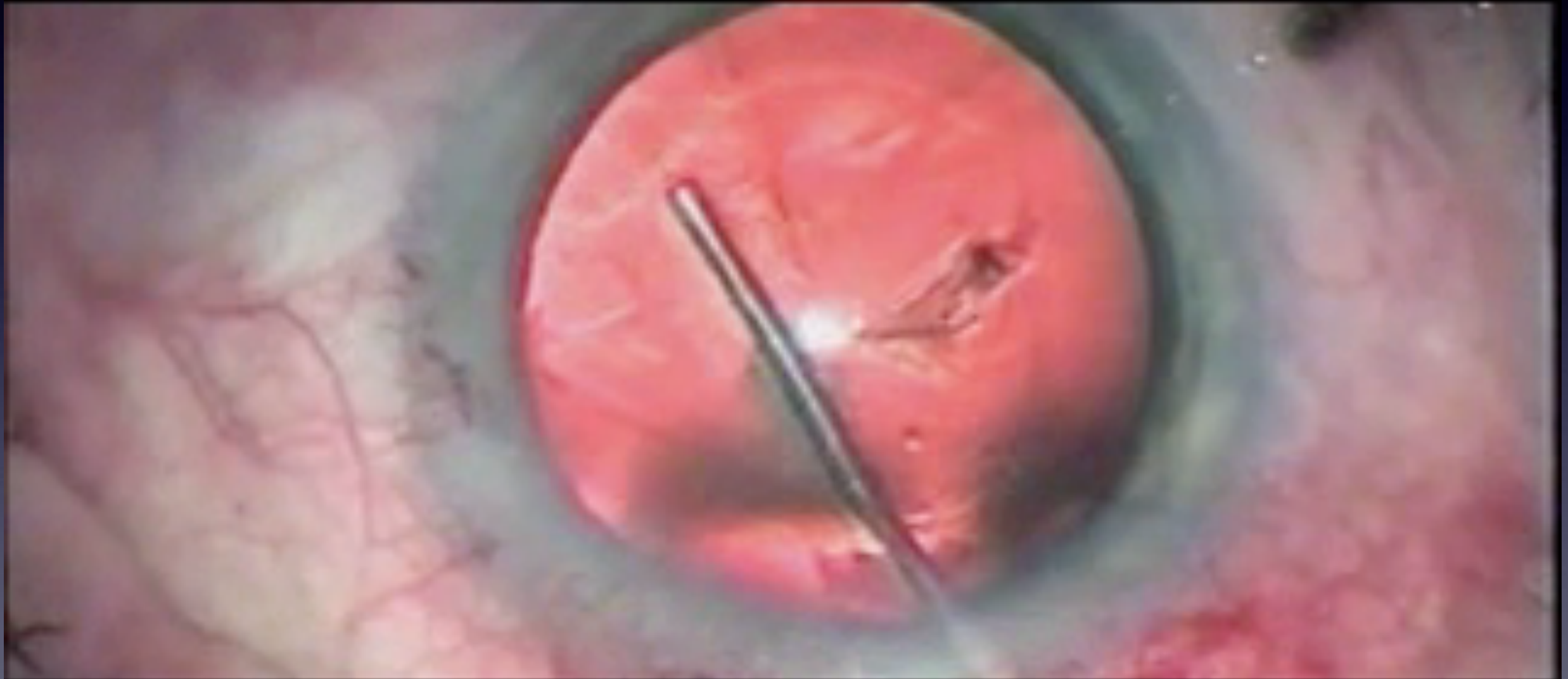
PCCC



Small Rhexis



CAPSULAR BLOCK



Incidence of Posterior Capsule Rupture

- **1.8% (1.4-3.4%).**
- **59.6% during Phacoemulsification.**
- **24.8% during I/A.**

AMERICAN JOURNAL
OF OPHTHALMOLOGY®

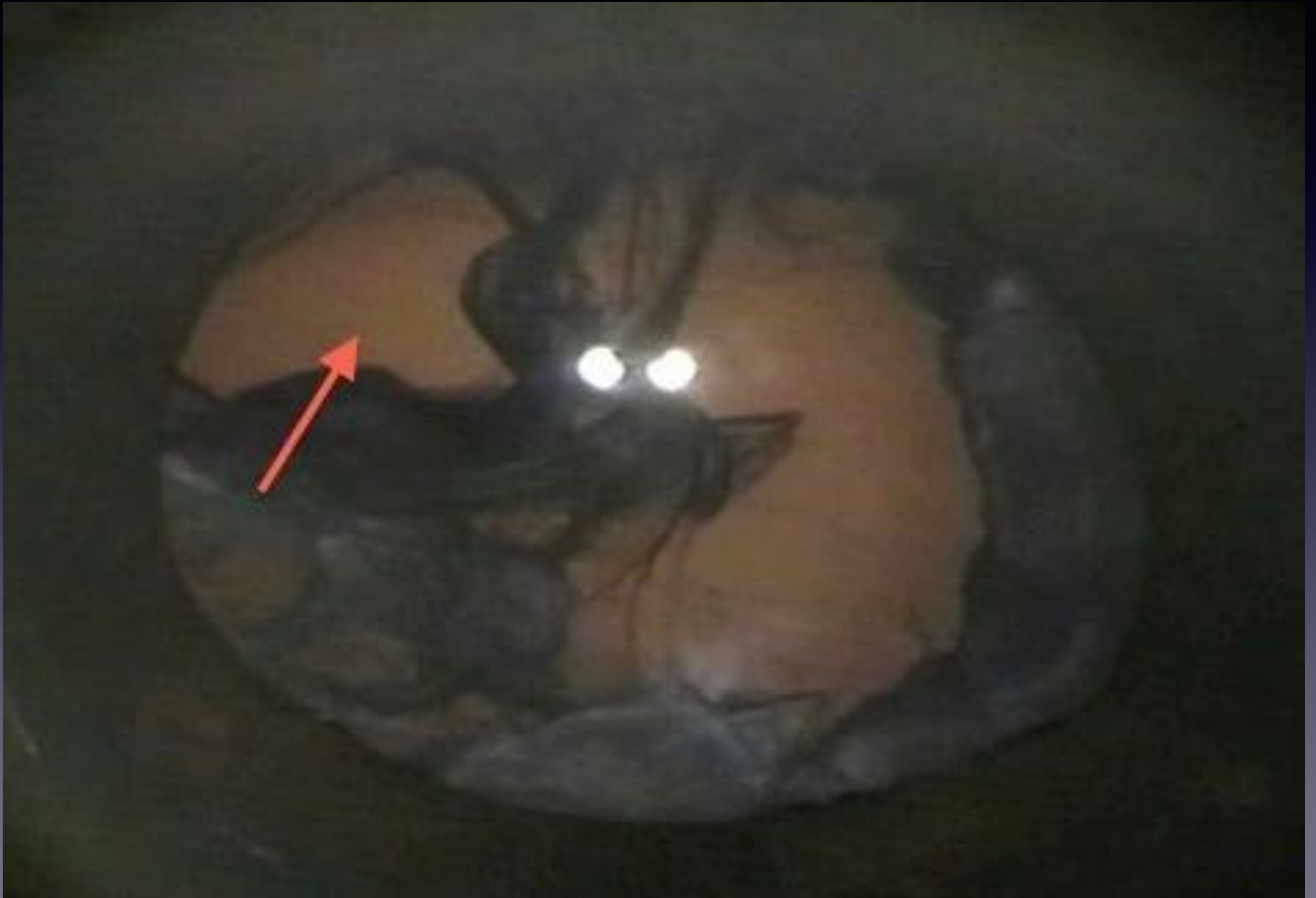January 2014 Volume 157, Issue 1, Pages 180–185.e1

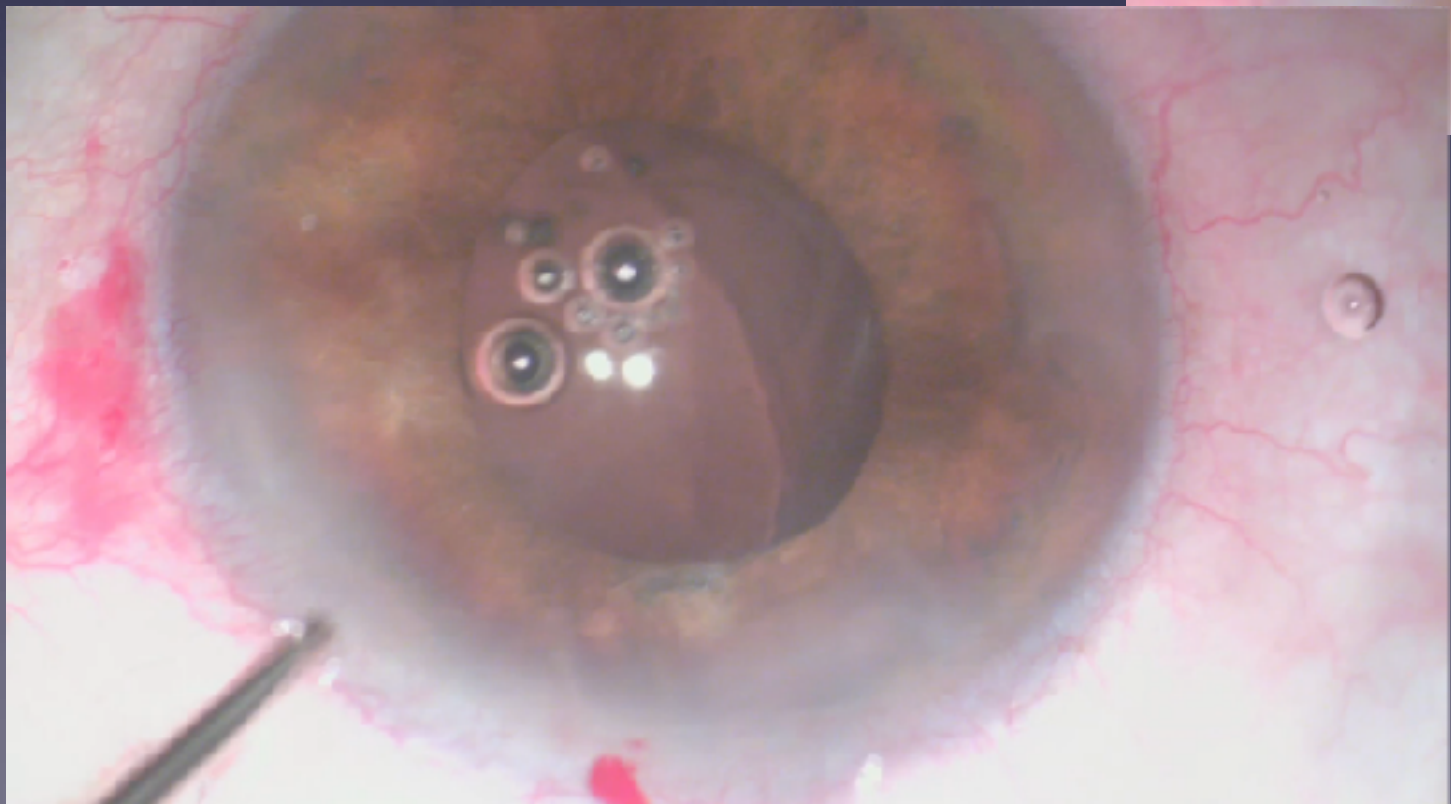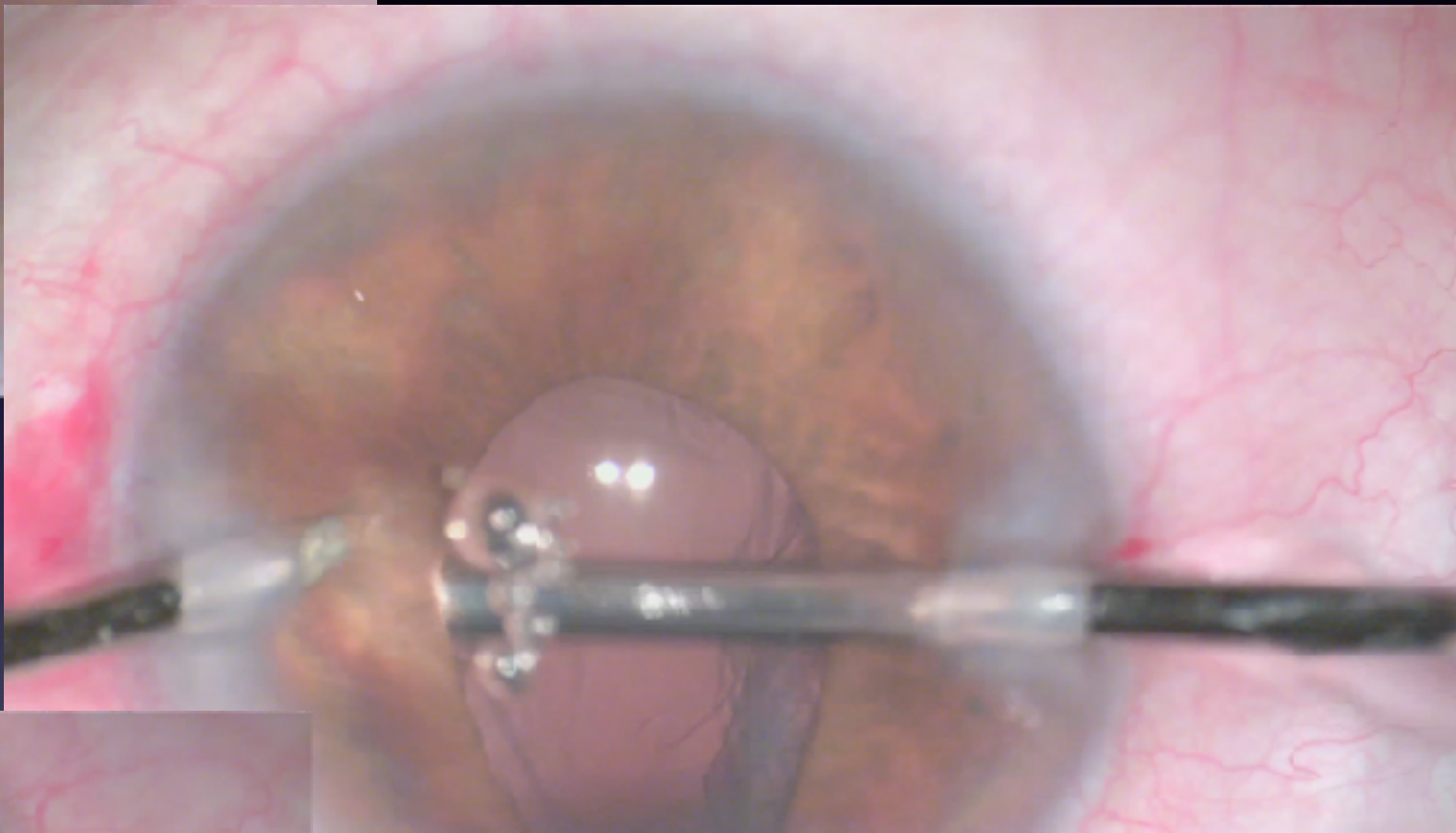



A 5-Year Audit of Cataract Surgery Outcomes After Posterior Capsule Rupture and Risk Factors Affecting Visual Acuity

[Seng-Ei Ti](#) , [You-Nian Yang](#), [Stephanie S. Lang](#), [Soon Phaik Chee](#)

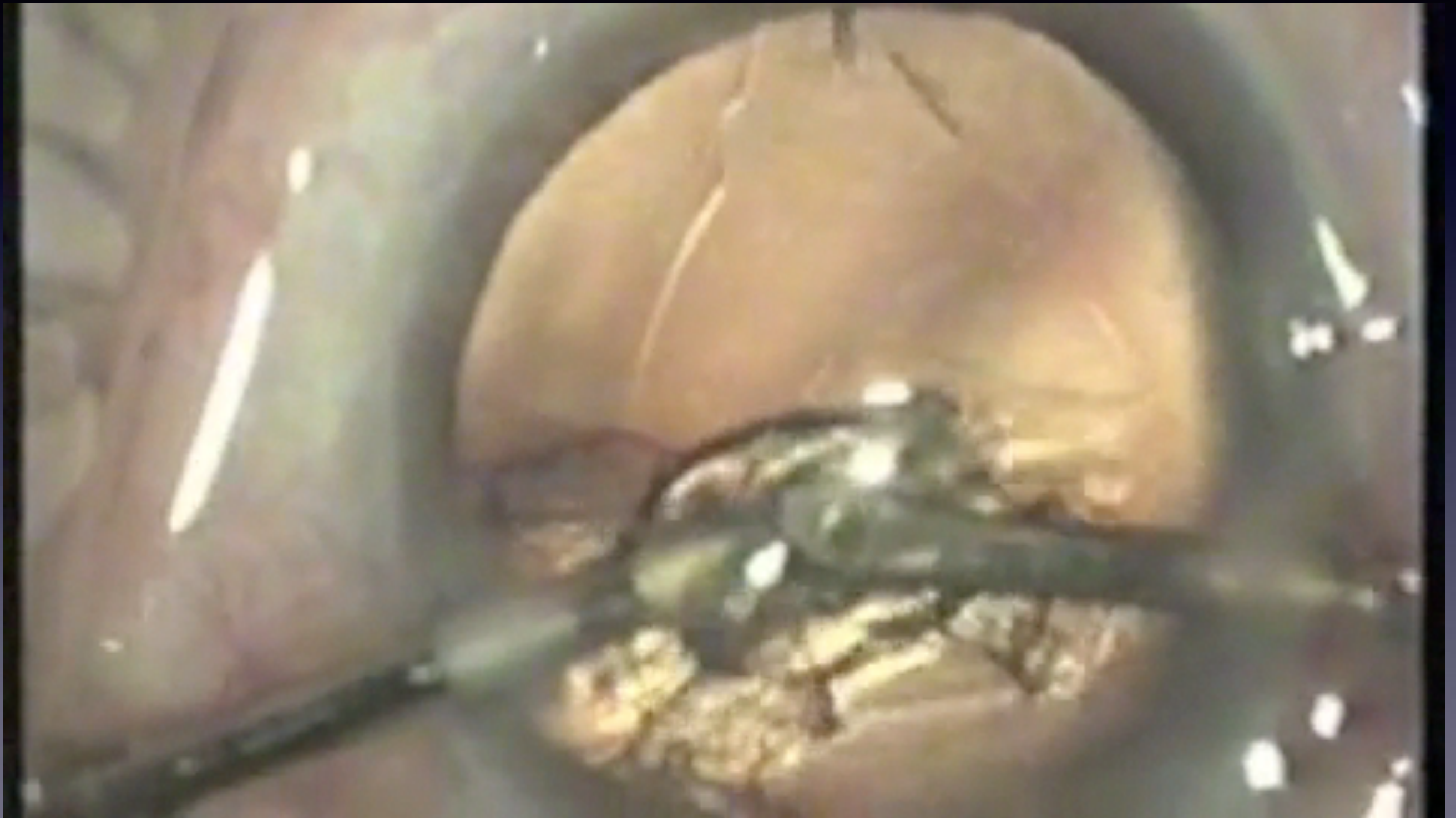
CAPSULE RUPTURE

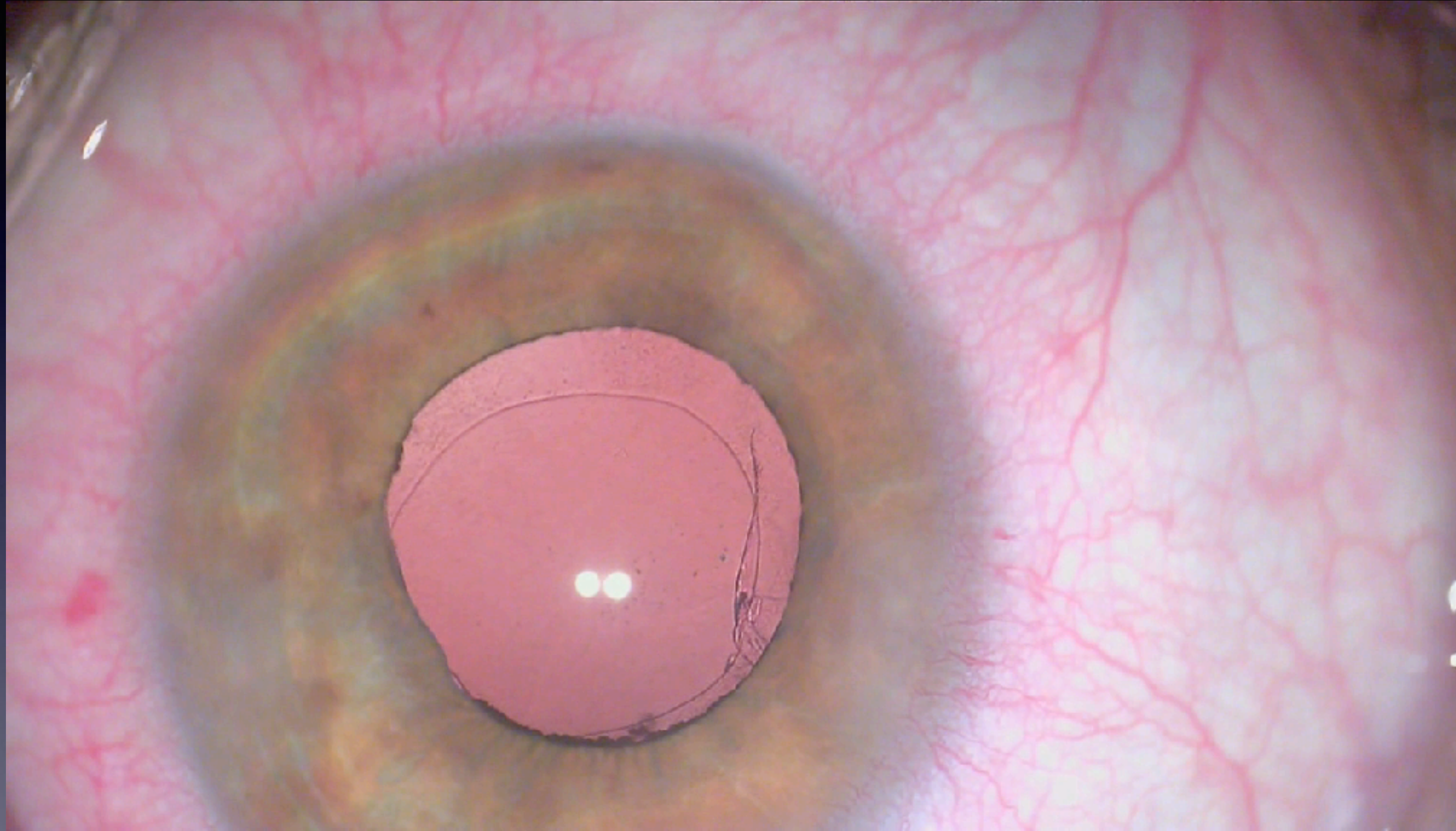






Extension during phaco





CONCLUSIONS

- Know about the capsule
- Feel it
- Understand its behaviour
- Then you will be fine

